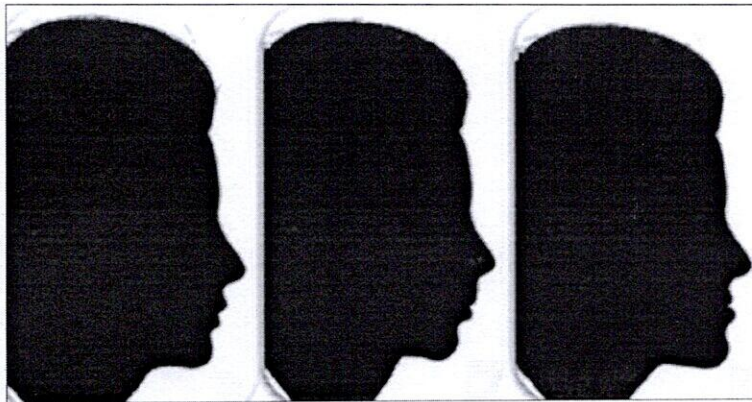


1. PROFILE – CASE HISTORY



NAME	PROFILE OF PATIENT
Description	Different conditions of facial profile while taking case history
Information about the scenario:	
The above picture shows the different types of facial profile related to different malocclusion	
At this station you are supposed to:	
<ol style="list-style-type: none"> 1. What are the points considered while checking profile of the patient. 2. What are the types of profiles?. 3. What are the clinical conditions related to the different types of profile. 	

MARKING PATTERN


Candidate Reg No:

Examined by:

List of Competency	Weightage	Done	Partially done	Not done
1.	1			
2.	2			
3.	2			
Marks obtained				Out of 5

Total marks out of 5

PRINCIPAL
SRI VENKATESHWARAA DENTAL COLLEGE
ARIYUR, PUDUCHERRY - 605 102.



OSCE- 3

MAXILLOFACIAL TRAUMA

ASSESSOR:

STUDENT:

S.no	Type of fracture	Clinical features	Relevant radiograph	Approach	Selection of plate	No of plate	PLATE Positioning	PLATE Bending	PLATE Fixing	TOTAL [8]
1.	Symphysis									
2.	Body of mandible									
3.	Angle of mandible									
4.	Leforte I									
5.	ZMC									

Global score:

1-poor

2- borderline

3- average

4- good

5 excellent.

PRINCIPAL
SRI VENKATESHWARA DENTAL COLLEGE
ARIYUR, PUDUCHERRY - 605 102.

OSCE- 4 WIRING

ASSESSOR:

STUDENT:

S.no	Type of wiring	Indication	Preparation	Accuracy of the technique	Finishing	TOTAL [4]
1.	Arch bar					
2.	Eyelet					
3.	IMF					
4.	Essigs					
5.	circummandibular					

Global score:

1-poor

2- borderline

3- average

4- good

5 excellent.

PRINCIPAL
SRI VENKATESHWARAA DENTAL COLLEGE
ARIYUR, PUDUCHERRY - 605 102.

OSCE-5 TMJ DISLOCATION

STUDENT:

ASSESSOR:

S.no	Criteria	Performed	Not performed
1.	History (precipitating factors)	1	0
2.	Clinical features	1	0
3.	Relevant radiographs	1	0
4.	Reduction technique		
	a. Patient position	1	0
	b. Operator position	1	0
	c. Operator finger position	1	0
	d. Direction of force	1	0
5.	Post-operative instructions		
	a. Soft diet	1	0
	b. Restriction in mouth opening	1	0
	c. IMF	1	0

Global score:

1-poor

2- borderline

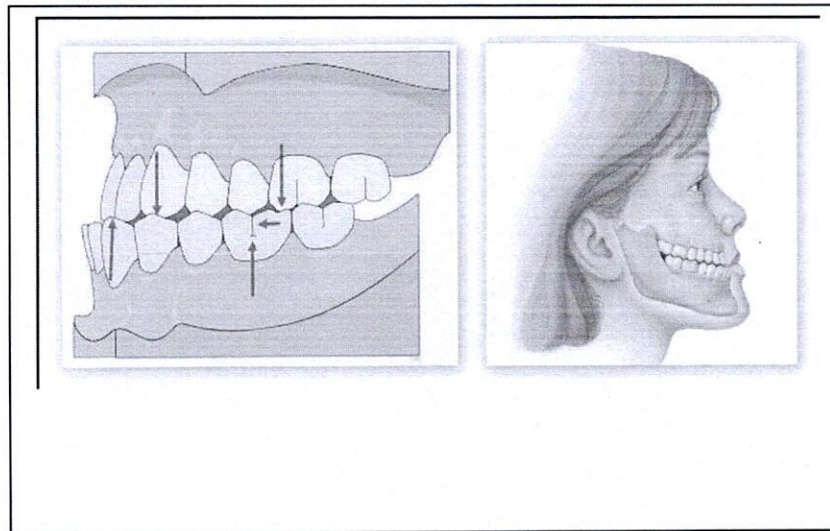
3- average

4- good

5 excellent.

PRINCIPAL
SRI VENKATESHWARAA DENTAL COLLEGE
ARIYUR, PUDUCHERRY - 605 102.

1. SKELETAL CLASS III MALOCCLUSION



NAME	SKELETAL CLASS III MALOCCLUSION
Description	Developmental malocclusion
Information about the scenario:	
The picture shows skeletal class III malocclusion with prognathic mandible and retrognathic maxilla	
At this station you are supposed to:	
Etiology of the condition	
Clinical and radiographic feature of the condition	
List down the management of the condition	

MARKING PATTERN


Candidate Reg No:

Examined by:

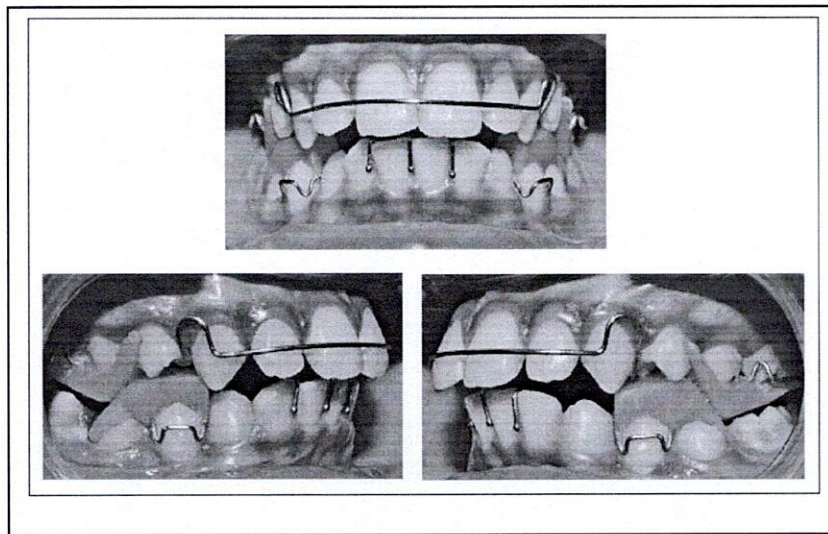
List of Competency	Weightage	Done	Partially done	Not done
1.	1			
2.	2			
3.	2			
Marks obtained				Out of 5

Total marks out of 5


PRINCIPAL
SRI VENKATESHWARAA DENTAL COLLEGE
ARIYUR, PUDUCHERRY - 605 102.



3 TWIN BLOCK.



NAME	TWIN BLOCK
Description	The given picture is a myofunctional appliance
Information about the scenario:	
The given picture is a myofunctional appliance	
At this station you are supposed to:	
<ol style="list-style-type: none"> 1. In which condition do we give this appliance? 2. parts of the appliance? 3. what is the angulation given to the inclined plane? 	

MARKING PATTERN


Candidate Reg No:

Examined by:

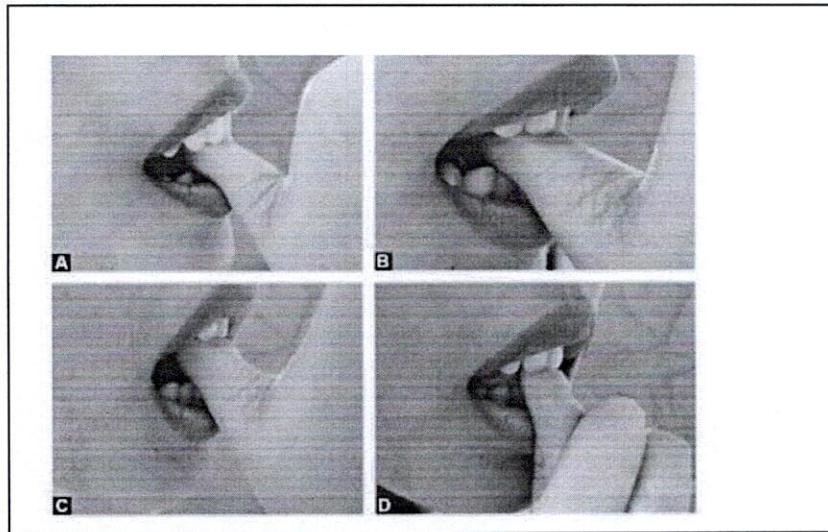
List of Competency	Weightage	Done	Partially done	Not done
1.	1			
2.	2			
3.	2			
Marks obtained				Out of 5

Total marks out of 5


PRINCIPAL
SRI VENKATESHWARAA DENTAL COLLEGE
ARIYUR, PUDUCHERRY - 605 002



1. THUMB SUCKING HABIT



NAME	THUMB SUCKING HABIT
Description	The given picture is an abnormal pressure habit
Information about the scenario:	
The given picture is a abnormal habit	
At this station you are supposed to:	
<ol style="list-style-type: none"> 1. clinical features of thumb sucking habit? 2. Classification of thumb sucking habit 3. write on reminder therapy 4. write on mechanical therapy? 5. 4.write on psychological therapy ? 	

MARKING PATTERN


Candidate Reg No:

Examined by:

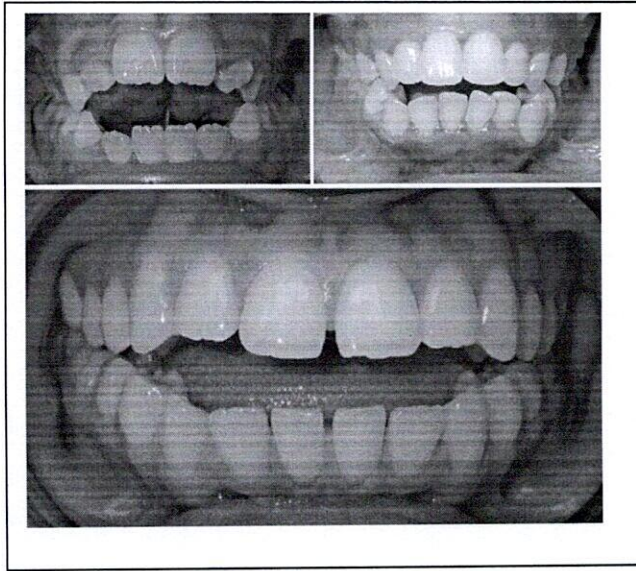
List of Competency	Weightage	Done	Partially done	Not done
1.	1			
2.	1			
3.	1			
4.	1			
5	1			
Marks obtained			Out of 5	

Total marks out of 5


PRINCIPAL
SRI VENKATESHWARAA DENTAL COLLEGE
ARIYUR, PUDUCHERRY



1. OPEN BITE



NAME	ANTERIOR OPEN BITE
Description	The given picture shows a anterior open bite condition
Information about the scenario:	
The given picture shows clinical condition of open bite	
At this station you are supposed to:	
<ol style="list-style-type: none"> 1. classification of open bite 2. etiology of openbite? 3. What is adenoid faces? 	

MARKING PATTERN


Candidate Reg No:

Examined by:


List of Competency	Weightage	Done	Partially done	Not done
1.	1			
2.	2			
3.	2			
Marks obtained				Out of 5

Total marks out of 5


PRINCIPAL
SRI VENKATESHWARAA DENTAL COLLEGE
ARIYUR, PUDUCHERRY - 605 102.



1. K FILE



NAME	1.K FILE
Description	THE PICTURE SHOWS K FILE
Information about the scenario: THE PICTURE SHOWS K FILE	
At this station you are supposed to:	
2. ENDODONTIC INSTRUMENT STANDARDISATION 3. FEATURES AND USES OF K FILE	

MARKING PATTERN

Candidate Reg No:

Examined by:

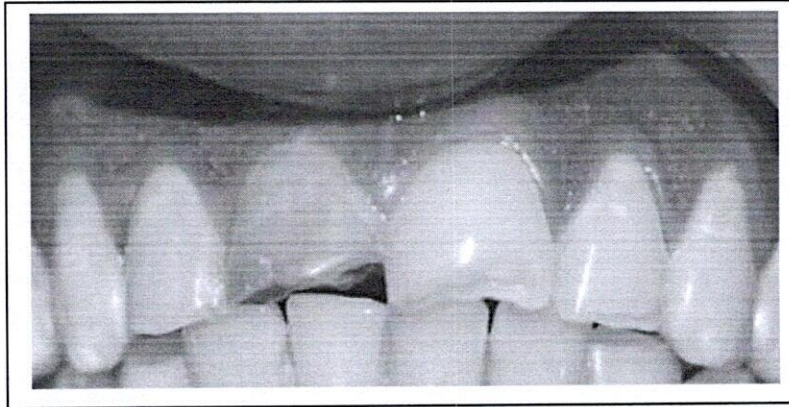
List of Competency	Weightage	Done	Partially done	Not done
1.	1			
2.	2			
3.	2			
Marks obtained				Out of 5

Total marks out of 5



PRINCIPAL
SRI VENKATESHWARAA DENTAL COLLEGE
 MEDICAL CAMPUS

1. ELLIS CLASS 1V IN 11 AND ELLIS II IN 21



NAME	1. ELLIS CLASS 1V IN 11 AND ELLIS II IN 21
Description	THE PICTURE SHOWS ELLIS CLASS 1V IN 11 AND ELLIS II IN 21
Information about the scenario: ELLIS CLASS 1V IN 11 AND ELLIS II IN 21	
At this station you are supposed to: ELLIS CLASS 1V IN 11 (NON VITAL)AND ELLIS II IN 11	
2. ELLIS CLASSIFICATION OF TRAUMA	
3. TREATMENT FOR ELLIS CLASS IV AND CLASS 11	


MARKING PATTERN

Candidate Reg No:

Examined by:

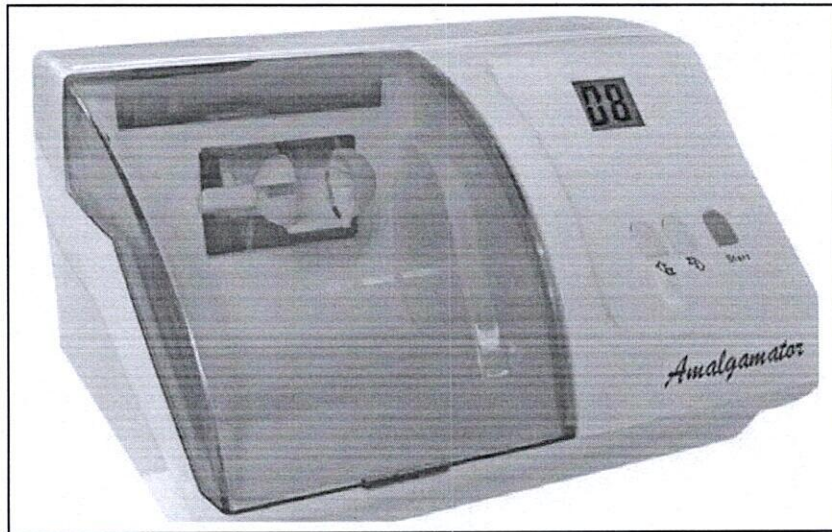
List of Competency	Weightage	Done	Partially done	Not done
1.	1			
2.	2			
3.	2			
Marks obtained				Out of 5

Total marks out of 5



PRINCIPAL
SRI VENKATESHWARAA DENTAL COLLEGE
ARIYUR, PUDUCHERRY - 605 102.

1. AMALGAMATOR



NAME	1.AMALGAMATOR
Description	THE PICTURE SHOWS AMALGAMATOR
Information about the scenario:	THE PICTURE SHOWS AMALGAMATOR
At this station you are supposed to:	
	2.WHAT IS PURPOSE OF AMALGAMATOR? 3.WHAT TYPE OF TRITURATION IT IS?

MARKING PATTERN


Candidate Reg No:

Examined by:

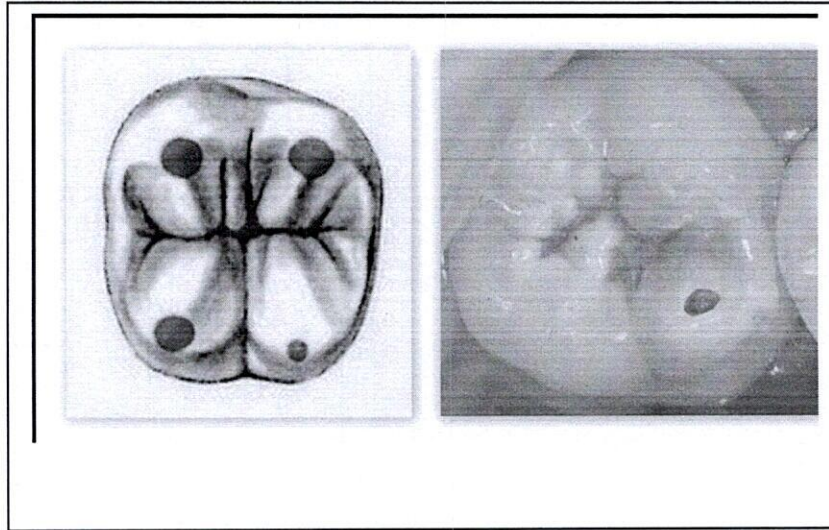
List of Competency	Weightage	Done	Partially done	Not done
1.	1			
2.	2			
3.	2			
Marks obtained				Out of 5

Total marks out of 5

PRINCIPAL
SRI VENKATESHWARAA DENTAL COLLEGE
ARIYUR, PUDUCHERRY



1. G V BLACK'S CLASSIFICATION CLASS VI



NAME	1. G V BLACK'S CLASSIFICATION CLASS VI
Description	THE PICTURE SHOWS CLASS VI DENTAL CARIES
Information about the scenario: THE PICTURE SHOWS CLASS VI DENTAL CARIES	
At this station you are supposed to:	
2. MUST KNOW G V BLACK'S FULL CLASSIFICATION	
3. WHAT ARE THE MATERIALS USED TO RESTORE CLASS VI CAVITY	

MARKING PATTERN

Candidate Reg No:

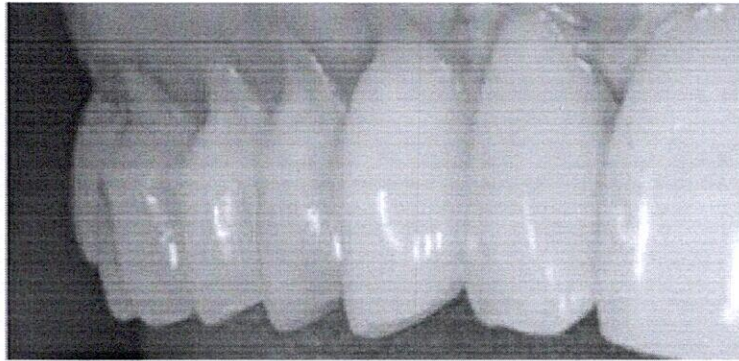
Examined by:

List of Competency	Weightage	Done	Partially done	Not done
1.	1			
2.	2			
3.	2			
Marks obtained				Out of 5

Total marks out of 5


PRINCIPAL
SRI VENKATESHWARAA DENTAL COLLEGE
ARIYUR, PUDUCHERRY - 605 102.

1. CERVICAL ABRASION



NAME	CERVICAL ABRASION
Description	Non-Carious Cervical Lesion
Information about the scenario:	
The picture shows pathological wearing away of teeth due to abnormal process, habits or abrasive substances.	
At this station you are supposed to:	
Etiology of the condition Symptoms associated with the condition List down the management of the condition	

MARKING PATTERN

Candidate Reg No:

Examined by:

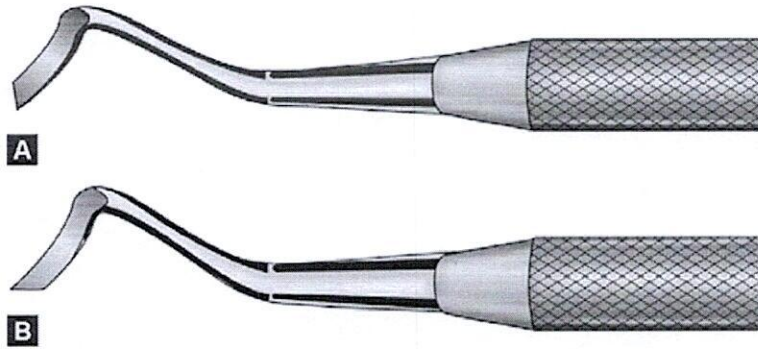
List of Competency	Weightage	Done	Partially done	Not done
1.	1			
2.	2			
3.	2			
Marks obtained			Out of 5	

Total marks out of 5

PRINCIPAL
SRI VENKATESHWARAA DENTAL COLLEGE
ARIYUR, PUDUCHERRY - 605 102.



1. GINGIVAL MARGINAL TRIMMER



NAME	GINGIVAL MARGINAL TRIMMER
Description	Used to give gingival cavo-surface bevel and rounding of axio-pulpal line angle.
Information about the scenario:	
The picture depicts Mesial and Distal gingival marginal trimmer.	
At this station you are supposed to:	
Instrument formula	
Identification of Mesial and Distal side	
Purpose of this instrument	

MARKING PATTERN

Candidate Reg No:

Examined by:

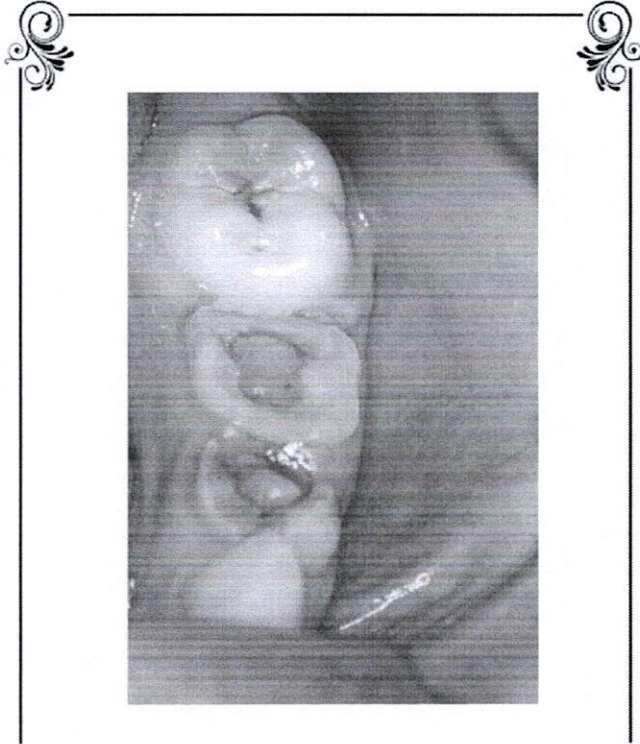List of Competency	Weightage	Done	Partially done	Not done
1.	1			
2.	2			
3.	2			
Marks obtained				Out of 5

Total marks out of 5

[Handwritten signature]

PRINCIPAL
SRI VENKATESHWARAA DENTAL COLLEGE
ARIYUR, PUDUCHERRY - 605 102.





NAME	Pulp polyp
Description	Grossly decayed tooth with pulp polyp
Information about the scenario:	
Patient reported with severe pain on left lower teeth	
At this station you are supposed to:	
Identify the lesion?	
Describe the lesion ?	
Write 2 differential diagnosis?	

MARKING PATTERN

Candidate Reg No:

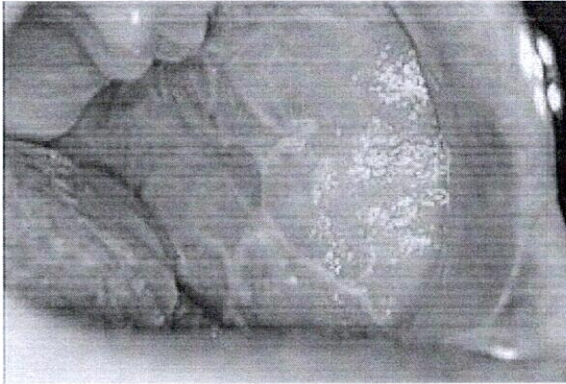
Examined by:

List of Competency	Weightage	Done	Partially done	Not done
1.	1			
2.	2			
3.	2			
Marks obtained				Out of 5

Total marks out of 5


 PRINCIPAL
 SRI VENKATESHWARAA DENTAL COLLEGE
 ARIYUR, PUDUCHERRY - 605 102.

1. ORAL LICHEN PLANUS



NAME	ORAL LICHEN PLANUS
Description	WHITE LESION – PATHOLOGICAL CONDITION
Information about the scenario:	
BUCCAL MUCOSA WITH WHITE LESION AND BURNING SENSATION	
At this station you are supposed to:	
1. IDENTIFY? 2. DESCRIBE THE LESION? 3. WRITE TWO DIFFERENTIAL DIAGNOSIS?	


MARKING PATTERN

Candidate Reg No:

Examined by:

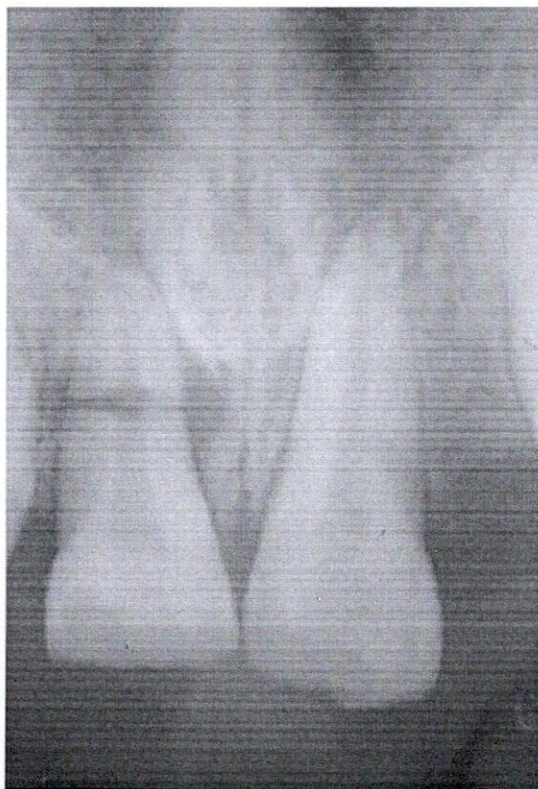List of Competency	Weightage	Done	Partially done	Not done
1.	2			
2.	1			
3.	2			
Marks obtained				Out of
5				

Total marks out of 5




 PRINCIPAL
SRI VENKATESHWARAS DENTAL COLLEGE
 ARIYUR, PUDUCHERRY - 605 102.

4. horizontal root fracture



NAME	Horizontal root fracture
Description	Radiograph of horizontal root fracture
Information about the scenario:	
Fracture at apical middle third junction – horizontal	
At this station you are supposed to:	
<ol style="list-style-type: none"> 1. write radiographic interpretation? 2. Give your radiographic diagnosis? 	

MARKING PATTERN


Candidate Reg No:

Examined by:

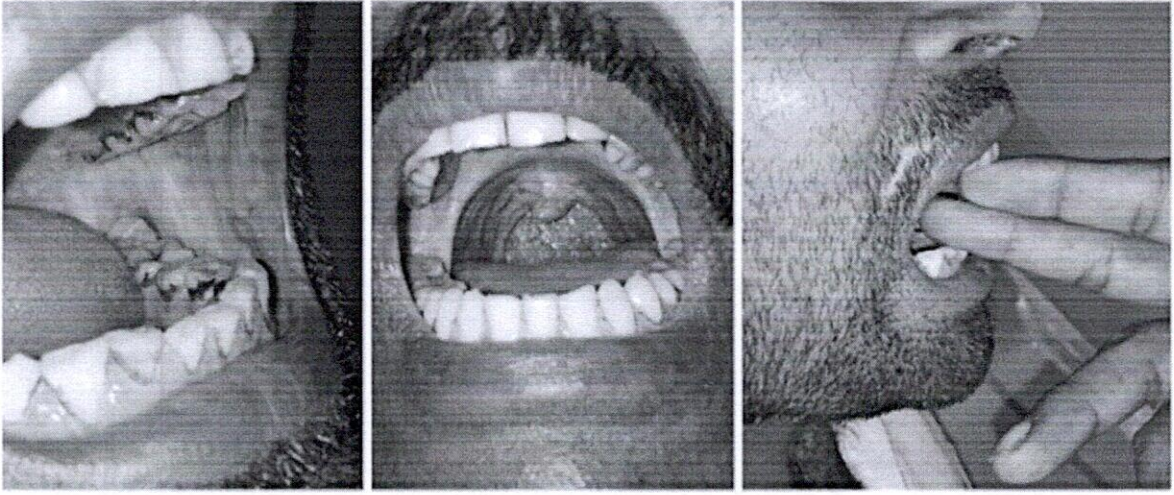
List of Competency	Weightage	Done	Partially done	Not done
1.	2.5			
2.	2.5			
Marks obtained				Out of 5

Total marks out of 5

PRINCIPAL
SRI VENKATESHWARAA DENTAL COLLEGE
ARIYUR, PUDUCHERRY - 605 102.



4. ORAL SUBMUCOSAL FIBROSIS



NAME	Oral submucosal fibrosis
Description	White band lesion with Restricted mouth opening
Information about the scenario:	
At this station you are supposed to:	
<ol style="list-style-type: none"> 1. Give your diagnosis? 2. Provisional diagnosis? 3. Treatment plan? 	

MARKING PATTERN

Candidate Reg No:

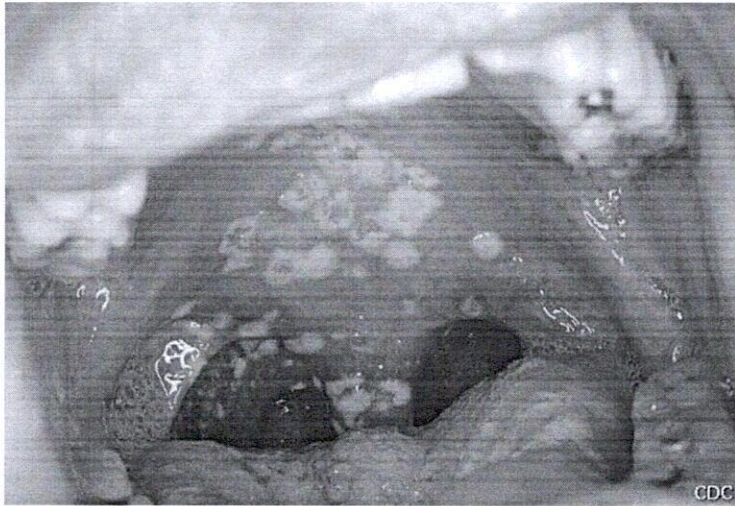
Examined by:

List of Competency	Weightage	Done	Partially done	Not done
1.	1			
2.	2			
3	2			
Marks obtained				Out of 5

Total marks out of 5

Dr. VENKATESH
ARIYUR, PUDUCHERRY - 605 102.

1. ORAL CANDIDIASIS



NAME	ORAL CANDIDIASIS
Description	WHITE LESION
Information about the scenario:	
WHITE LESION ON SOFT PALATE REGION	
At this station you are supposed to:	
<ol style="list-style-type: none"> 1. Describe the lesion 2. Write 2 differential diagnosis 3. Treatment option 	


MARKING PATTERN

Candidate Reg No:

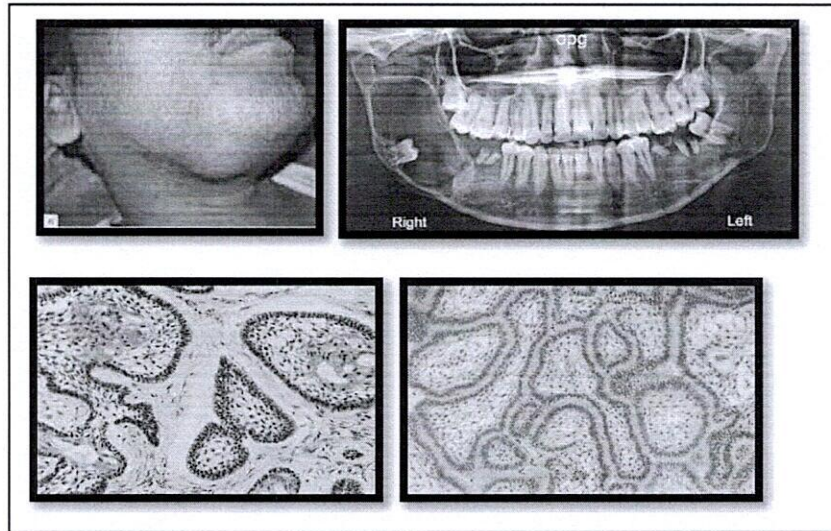
Examined by:

List of Competency	Weightage	Done	Partially done	Not done
1.	2			
2.	1			
3.	2			
Marks obtained				Out of
5				

Total marks out of 5


PRINCIPAL
SRI VENKATESHWARAA DENTAL COLLEGE
ARIYUR, PUDUCHERRY - 605 102.

AMELOBLASTOMA



NAME	Ameloblastoma
Description	The given picture is identified as Ameloblastoma
Information about the scenario:	
The given picture is a tumor	
At this station you are supposed to:	
<ol style="list-style-type: none"> 1. Definition? 2. Radiographic Feature? 3. H/Classification? 4. How to manage? 	

MARKING PATTERN

Candidate Reg No: _____

Examined by: _____

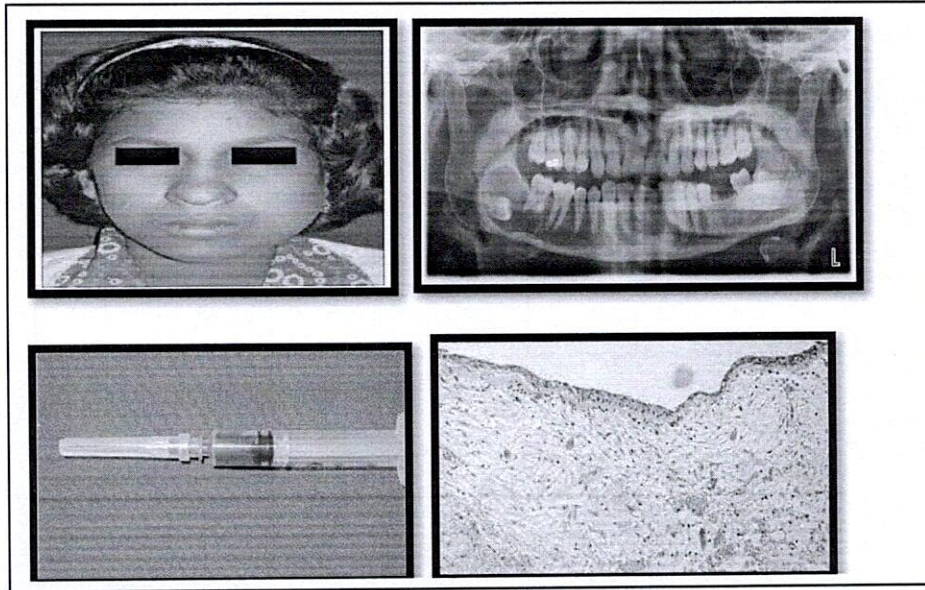
List of Competency	Weightage	Done	Partially done	Not done
1.	1			
2.	1			
3.	1			
4.	1			
5	1			
Marks obtained				Out of
5				

Total marks out of 5

PRINCIPAL
 SRI VENKATESHWARAA DENTAL COLLEGE
 ARIYUR, PUDUCHERRY - 605 102.



DENTIGEROUS CYST



NAME	DENTIGEROUS CYST
Description	The given picture is identified as Dentigerous cyst
Information about the scenario:	
The given picture is a Cystic Lesion	
At this station you are supposed to:	
<ol style="list-style-type: none"> 1. Define Dentigerous Cyst? 2. Pathogenesis? 3. Radiographic Types? 4. Potential Complications? 	

MARKING PATTERN


Candidate Reg No: _____

Examined by: _____

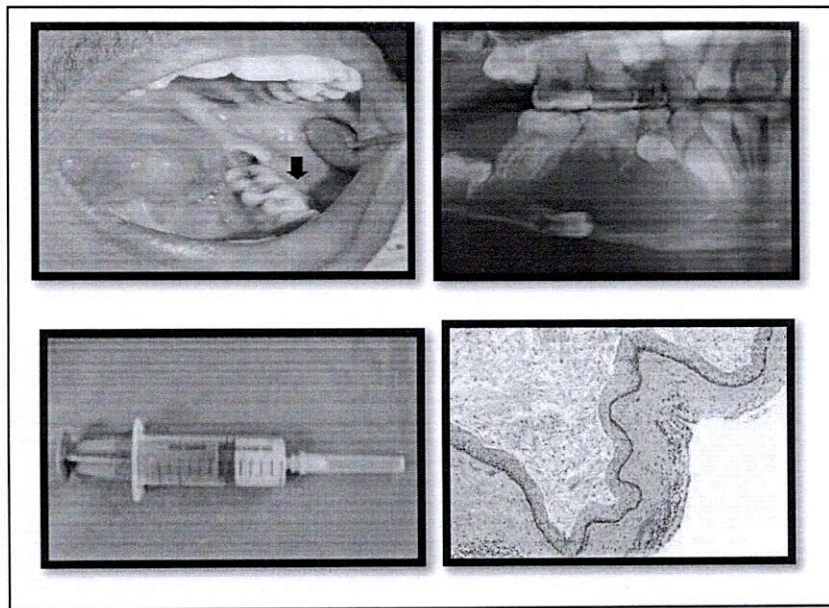
List of Competency	Weightage	Done	Partially done	Not done
1.	1			
2.	2			
3.	2			
Marks obtained				Out of
5				

Total marks out of 5


PRINCIPAL
SRI VENKATESHWARAA DENTAL COLLEGE
ARIYUR, PUDUCHERRY - 605 102



ODONTOGENIC KERATOCYST



NAME	ODONTOGENIC KERATOCYST
Description	The given picture is identified as OKC

Information about the scenario:
The given picture is a Cystic Lesion
At this station you are supposed to:
<ol style="list-style-type: none"> 1. Origin of OKC? 2. Clinical Behaviour of OKC ? 3. Management of OKC ? 4. Recurrence of OKC?


MARKING PATTERN

Candidate Reg No: _____

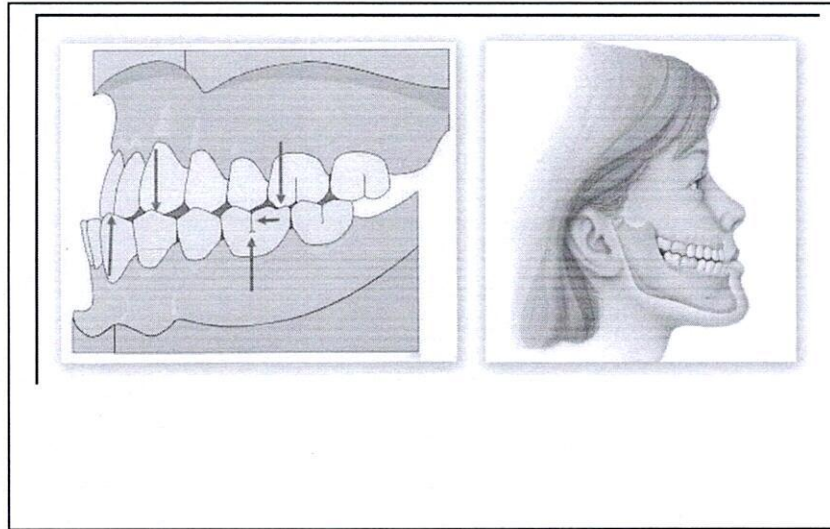
Examined by: _____

List of Competency	Weightage	Done	Partially done	Not done
1.	1			
2.	2			
3.	2			
Marks obtained				Out of 5

Total marks out of 5
PRINCIPAL
SRI VENKATESHWARAA DENTAL COLLEGE
ARIYUR, PUDUCHERRY - 605 102.



1. SKELETAL CLASS III MALOCCLUSION



NAME	SKELETAL CLASS III MALOCCLUSION
Description	Developmental malocclusion
Information about the scenario:	
The picture shows skeletal class III malocclusion with prognathic mandible and retrognathic maxilla	
At this station you are supposed to:	
Etiology of the condition	
Clinical and radiographic feature of the condition	
List down the management of the condition	

MARKING PATTERN

Candidate Reg No:

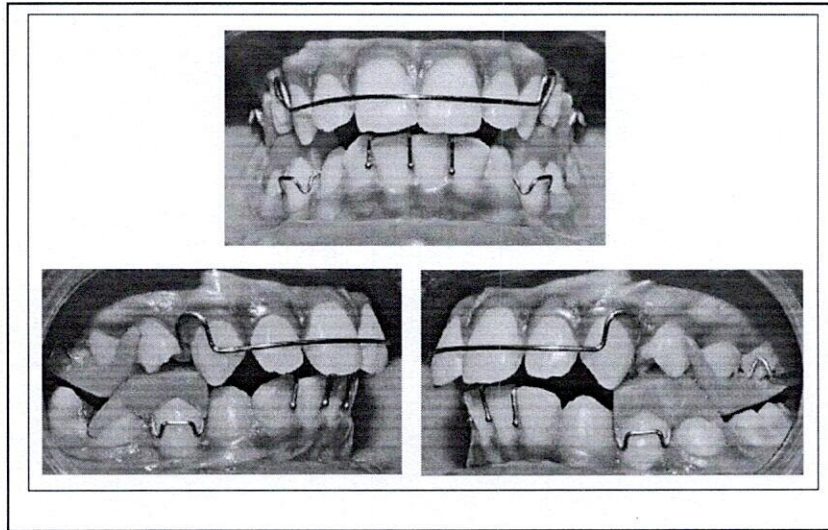
Examined by:

List of Competency	Weightage	Done	Partially done	Not done
1.	1			
2.	2			
3.	2			
Marks obtained				Out of 5

Total marks out of 5


PRINCIPAL
SRI VENKATESHWARAA DENTAL COLLEGE
ARIYUR, PUDUCHERRY - 605 102.

3 TWIN BLOCK.



NAME	TWIN BLOCK
Description	The given picture is a myofunctional appliance
Information about the scenario:	
The given picture is a myofunctional appliance	
At this station you are supposed to:	
<ol style="list-style-type: none"> 1. In which condition do we give this appliance? 2. parts of the appliance? 3. what is the angulation given to the inclined plane? 	

MARKING PATTERN

Candidate Reg No:


Examined by:

List of Competency	Weightage	Done	Partially done	Not done
1.	1			
2.	2			
3.	2			

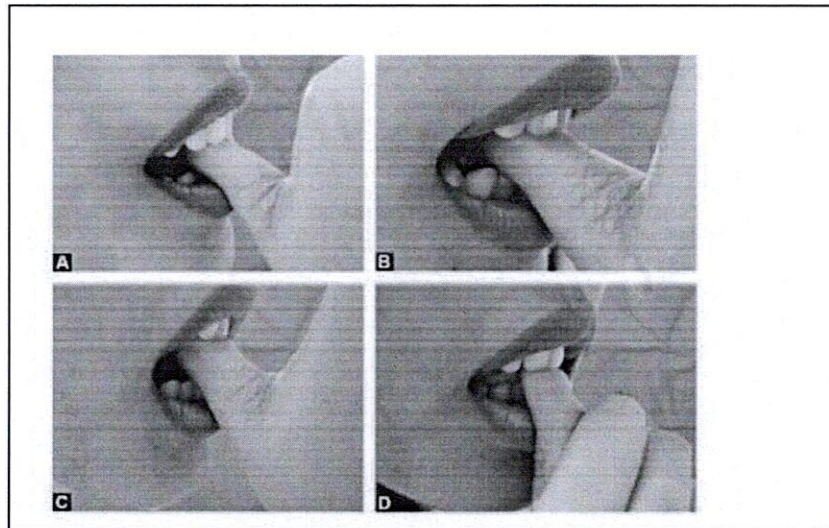
Marks obtained

Out of 5

Total marks out of 5


PRINCIPAL
SRI VENKATESHWARAA DENTAL COLLEGE
ARIYUR, PUDUCHERRY - 605 102.

1. THUMB SUCKING HABIT



NAME	THUMB SUCKING HABIT
Description	The given picture is an abnormal pressure habit
Information about the scenario:	
The given picture is a abnormal habit	
At this station you are supposed to:	
<ol style="list-style-type: none"> 1. clinical features of thumb sucking habit? 2. Classification of thumb sucking habit 3. write on reminder therapy 4. write on mechanical therapy? 5. 4.write on psychological therapy ? 	

MARKING PATTERN

Candidate Reg No:

Examined by:

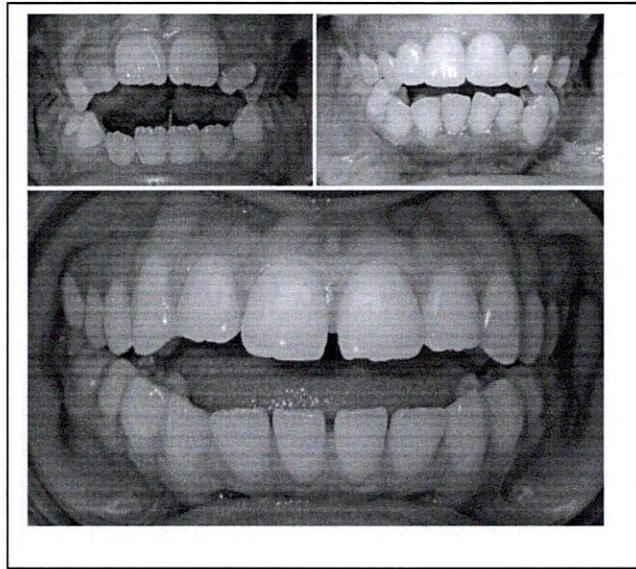
List of Competency	Weightage	Done	Partially done	Not done
1.	1			
2.	1			
3.	1			
4.	1			
5	1			
Marks obtained				Out of 5

Total marks out of 5

PRINCIPAL
SRI VENKATESHWARAA DENTAL COLLEGE
ARIYUR, PUDUCHERRY - 605 102.



1. OPEN BITE



NAME	ANTERIOR OPEN BITE
Description	The given picture shows a anterior open bite condition
Information about the scenario:	
The given picture shows clinical condition of open bite	
At this station you are supposed to:	
<ol style="list-style-type: none"> 1. classification of open bite 2. etiology of openbite? 3. What is adenoid faces? 	

MARKING PATTERN


Candidate Reg No:

Examined by:

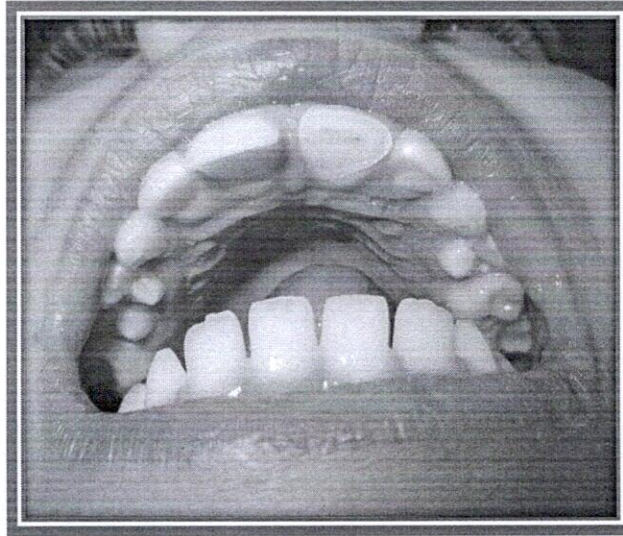
List of Competency	Weightage	Done	Partially done	Not done
1.	1			
2.	2			
3.	2			
Marks obtained			Out of 5	

Total marks out of 5

PRINCIPAL
SRI VENKATESHWARAA DENTAL COLLEGE
ARIYUR, PUDUCHERRY - 605 102.



1. ELLIS CLASS III IN 21



NAME	1.ELLIS CLASS III IN 21
Description	THE PICTURE SHOWS ELLIS CLASS III IN 21
Information about the scenario:	ELLIS CLASS III IN 21
At this station you are supposed to:	ELLIS CLASS III IN 21
2. ELLIS CLASSIFICATION OF TRAUMA 3. TREATMENT FOR ELLIS CLASS III	


MARKING PATTERN

Candidate Reg No:

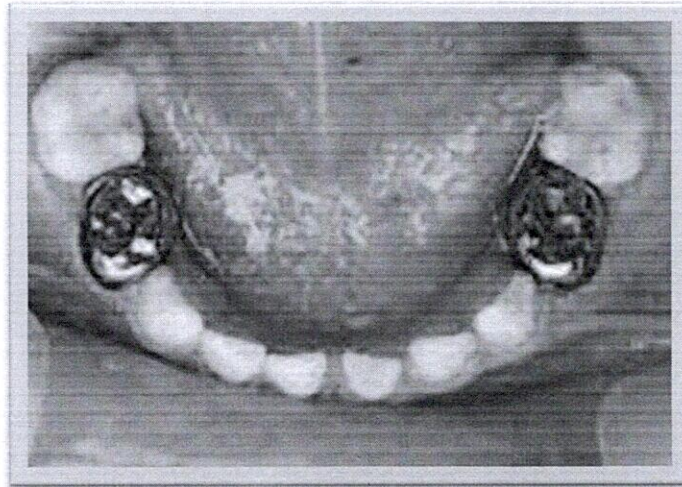
Examined by:

List of Competency	Weightage	Done	Partially done	Not done
1.	1			
2.	2			
3.	2			
Marks obtained				Out of 5

Total marks out of 5


PRINCIPAL
SRI VENKATESWARARAO COLLEGE
ARIYUR, PUDUCHERRY - 605 102.

2. STAINLESS STEEL CROWN



NAME	1. STAINLESS STEEL CROWN
Description	THE PICTURE SHOWS STAINLESS STEEL CROWN
Information about the scenario: STAINLESS STEEL CROWN IN RELATION TO 74 AND 84	
At this station you are supposed to:	
<ol style="list-style-type: none"> 1. INDICATIONS OF STAINLESS STEEL CROWNS 2. COMPOSITION OF STAINLESS STEEL CROWNS 	

MARKING PATTERN

Candidate Reg No:

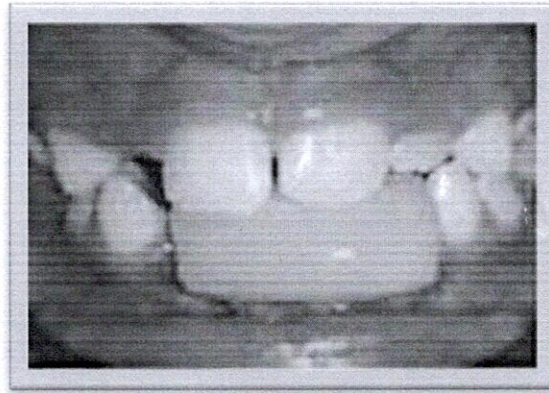
Examined by:

List of Competency	Weightage	Done	Partially done	Not done
1.	1			
2.	2			
3.	2			
Marks obtained				Out of 5

Total marks out of 5


PRINCIPAL
SRI VENKATESHWARAA DENTAL COLLEGE
ARIYUR, PUDUCHERRY - 605 102.

3. CATALANS APPLIANCE



NAME	1. CATALANS APPLIANCE
Description	THE PICTURE SHOWS CATALNAVS APPLIANCE
Information about the scenario: CATALANS APPLIANCE	
At this station you are supposed to:	
2. INDICATIONS OF CATALANS APPLIANCE	
3. MECANISM OF ACTION OF THE APPLIANCE	

MARKING PATTERN

Candidate Reg No:

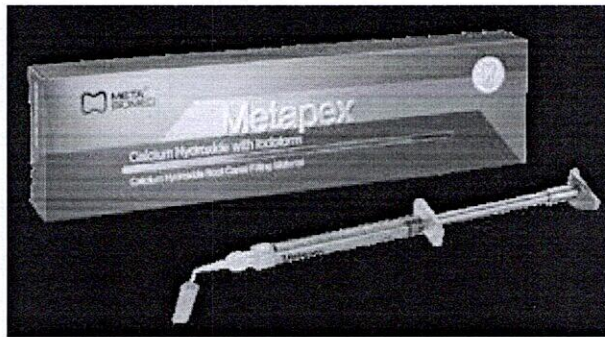Examined by:

List of Competency	Weightage	Done	Partially done	Not done
1.	1			
2.	2			
3.	2			
Marks obtained				Out of 5

Total marks out of 5

PRINCIPAL
SRI VENKATESHWARAA DENTAL COLLEGE
ARIYUR, PUDUCHERRY - 605 102.

4. METAPEX



NAME	1. METAPEX
Description	THE PICTURE SHOWS METAPEX
Information about the scenario: METAPEX	
At this station you are supposed to:	
<ol style="list-style-type: none"> 1. COMPOSITION 2. OTHER OBTURATING MATERIALS 	

MARKING PATTERN

Candidate Reg No:

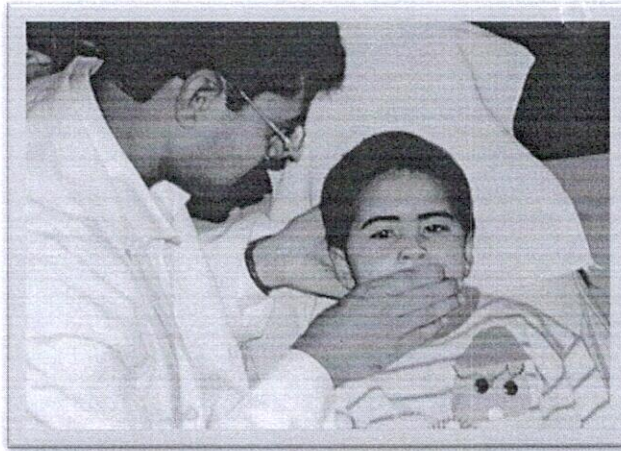
Examined by:

List of Competency	Weightage	Done	Partially done	Not done
1.	1			
2.	2			
3.	2			
Marks obtained				Out of 5

Total marks out of 5


PRINCIPAL
SRI VENKATESHWARAA DENTAL COLLEGE
ARIYUR, PUDUCHERRY - 605 102.

4. HOME



NAME	1. HOME
Description	THE PICTURE SHOWS HOME TECHNIQUE
Information about the scenario: HOME TECHNIQUE OF BEHAVIOUR MANAGEMENT	
At this station you are supposed to:	
<ol style="list-style-type: none"> 1. FULL FORM OF HOME 2. INTRODUCED BY... 	

MARKING PATTERN

Candidate Reg No:

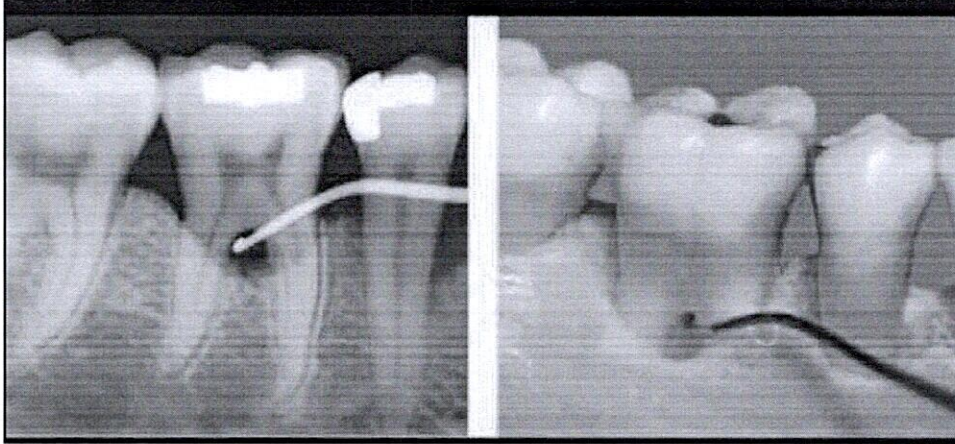Examined by:

List of Competency	Weightage	Done	Partially done	Not done
1.	1			
2.	2			
3.	2			
Marks obtained				Out of 5

Total marks out of 5

PRINCIPAL
SRI VENKATESHWARAA DENTAL COLLEGE
ARIYUR, PUDUCHERRY - 605 102.

1. Furcation involvement



NAME	FURCATION INVOLVEMENT
Description	The given picture shows Furcation involvement in lower posterior tooth
Information about the scenario:	
The given picture shows clinical condition of furcation involvement	
At this station you are supposed to:	
<ol style="list-style-type: none"> 1. Definition? 2. Classification of Furcation? 3. Treatment Option? 	

MARKING PATTERN


Candidate Reg No:

Examined by:

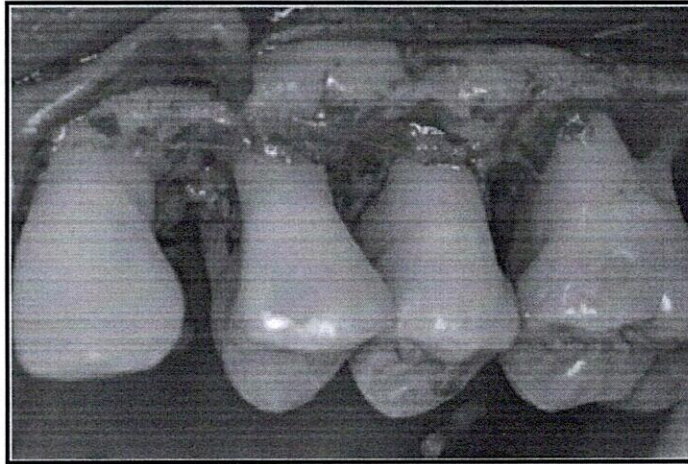
List of Competency	Weightage	Done	Partially done	Not done
1.	2			
2.	1			
3.	2			
Marks obtained 5				Out of

Total marks out of 5

PRINCIPAL
SRI VENKATESHWARA DENTAL COLLEGE
ARIYUR, PUDUCHERRY - 605 102.



4. Osseous defect



NAME	Osseous defect
Description	The given picture shows Bulbous contour
Information about the scenario:	
The given picture shows clinical condition of osseous defect	
At this station you are supposed to:	
1. Definition of osseous defect? 2. Type of defect? 3. Treatment option?	

MARKING PATTERN

Candidate Reg No:

Examined by:

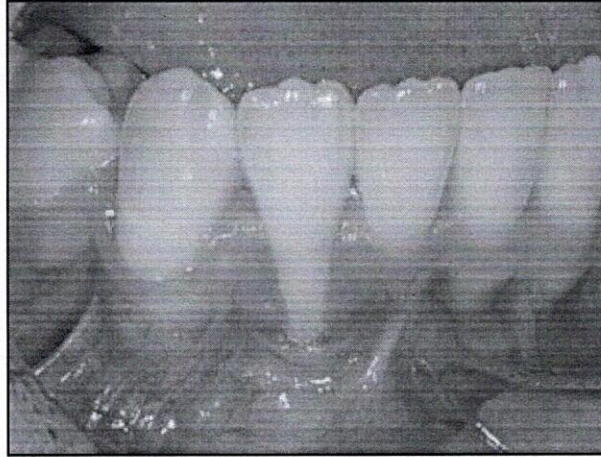List of Competency	Weightage	Done	Partially done	Not done
1.	2			
2.	1			
3.	2			
Marks obtained				Out of
5				

Total marks out of 5




PRINCIPAL
SRI VENKATESHWARAA DENTAL COLLEGE
ARIYUR, PUDUCHERRY - 605 102.

5. Gingival recession



NAME	GINGIVAL RESSION
Description	The given picture shows Gingival recession in relation to 42
Information about the scenario:	
The given picture shows clinical condition of gingival recession	
At this station you are supposed to:	
<ol style="list-style-type: none"> 1. Classification of gingival recession? 2. Etiology of recession? 3. Treatment Option? 	

MARKING PATTERN


Candidate Reg No:

Examined by:

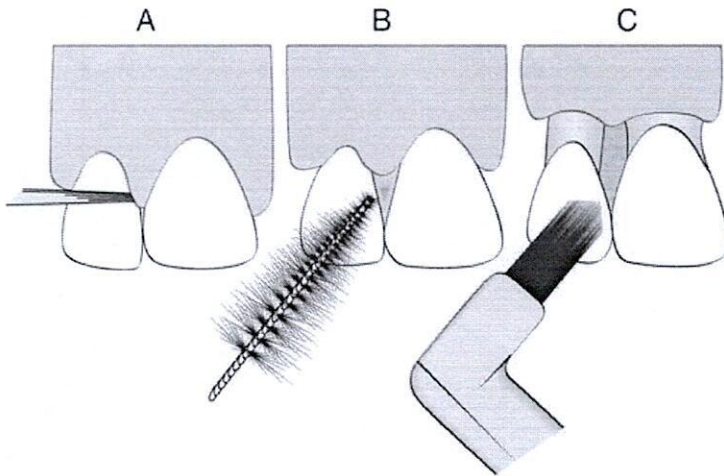
List of Competency	Weightage	Done	Partially done	Not done
1.	2			
2.	1			
3.	2			
Marks obtained 5				Out of

Total marks out of 5


PRINCIPAL
SRI VENKATESHWARAA DENTAL COLLEGE
ARIYUR, PUDUCHERRY - 605 102.



1. INTERDENTAL EMBRASSURES AND INTER DENTAL CLEANING AIDS



NAME	INTERDENTAL EMBRASSURES AND inter dental aids.
Description	The given picture shows types of embrasures and interdental aids.
Information about the scenario:	
The given picture shows clinical condition of interdental embrasures and interdental aids.	
At this station you are supposed to:	
<ol style="list-style-type: none"> 1. Types of embrasures? 2. Types of inter dental aids? 3. How to use these aids? 	


MARKING PATTERN

Candidate Reg No:

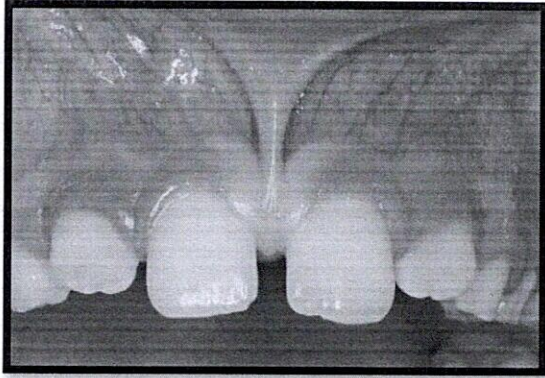
Examined by:

List of Competency	Weightage	Done	Partially done	Not done
1.	2			
2.	1			
3.	2			
Marks obtained 5				Out of

PRINCIPAL
SRI VENKATESHWARAA DENTAL COLLEGE
ARIYUR, PUDUCHERRY - 605 102.



1. HIGH FRENAL ATTACHMENT



NAME	HIGH FRENAL ATTACHMENT
Description	High maxillary labial frenum
Information about the scenario:	
The picture shows high maxillary labial frenum with papillary type of attachment	
At this station you are supposed to:	
Types of frenal attachment	
Tests to diagnose high frenal attachment	
Treatment	

MARKING PATTERN

Candidate Reg No:

Examined by:

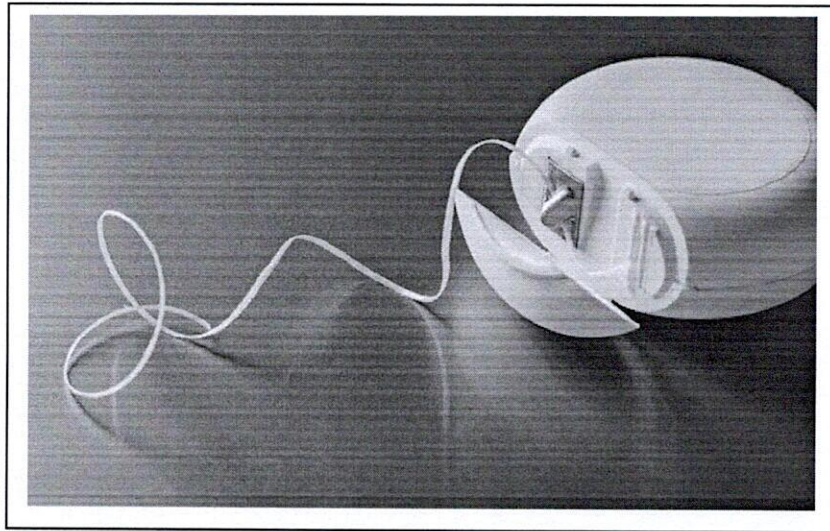
List of Competency	Weightage	Done	Partially done	Not done
1.	1			
2.	2			
3.	2			
Marks obtained			Out of 5	

Total marks out of 5

PRINCIPAL

**JRI VENKATESHWARAA DENTAL COLLEGE
ARIYUR, PUDUCHERRY - 605 102**

1. DENTAL FLOSS



NAME	DENTAL FLOSS
Description	Mechanical plaque control (Supplemental)
Information about the scenario:	
The picture shows a mechanical plaque control supplemental aid	
At this station you are supposed to:	
Classify dental floss	
Advantages and disadvantages	


MARKING PATTERN

Candidate Reg No:


Examined by:

List of Competency	Weightage	Done	Partially done	Not done
1. Knowledge	1 2.5			
2. Knowledge	2. 2.5			
Marks obtained				Out of 5

Total marks out of 5


PRINCIPAL
SRI VENKATESHWARAA DENTAL COLLEGE
ARIYUR, PUDUCHERRY - 605 102.

2. Mouthrinse containing chlorhexidine



NAME	MOUTHRINSE CONTAINING CHLORHEXIDINE
Description	Chemical plaque control agent
Information about the scenario:	
The picture shows a bottle of mouthrinse containing chlorhexidine	
At this station you are supposed to:	
Enumerate Chemical Composition	
Mechanism of action	

MARKING PATTERN

Candidate Reg No:


Examined by:

List of Competency	Weightage	Done	Partially done	Not done
1. Knowledge	2.5			
2. Knowledge	2.5			
Marks obtained			Out of 5	

Total marks out of 5

PRINCIPAL
SRI VENKATESHWARAA DENTAL COLLEGE
ARIYUR, PUDUCHERRY - 605 102.

3. Pit and Fissure sealant material



NAME	PIT AND FISSURE SEALANT
Description	Material used for dental preventive procedure
Information about the scenario:	
The picture shows a syringe containing sealant material	
At this station you are supposed to:	
Enumerate types of fissures	
Classify pit and fissure sealants based on generation	
How would you evaluate the success of your procedure in the last step	

MARKING PATTERN


Candidate Reg No:

Examined by:


List of Competency	Weightage	Done	Partially done	Not done
1. Knowledge	1.67			
2. Knowledge	1.66			
3. Technique	1.67			
Marks obtained			Out of 5	

Total marks out of 5

PRINCIPAL
SRI VENKATESHWARAA DENTAL COLLEGE
ARIYUR, PUDUCHERRY - 605 102.



4. Quit smoking Campaign



NAME	Quit Smoking Campaign
Description	A pictorial representation to stop smoking
Information about the scenario:	
The picture gives a message to stop smoking	
At this station you are supposed to:	
List the stages of change in of Trans-theoretical model associated with tobacco cessation	
List the 5 A's associated with tobacco cessation	


MARKING PATTERN

Candidate Reg No:


Examined by:

List of Competency	Weightage	Done	Partially done	Not done
1. Counselling Skills	2.5			
2. Knowledge	2.5			
Marks obtained			Out of 5	

Total marks out of 5


 PRINCIPAL
 SRI VENKATESHWARAA DENTAL COLLEGE
 ARIYUR, PUDUCHERRY - 605 102.

5. Dentifrice



NAME	DENTRIFICE
Description	A cleaning and polishing agent for tooth surface
Information about the scenario:	
The picture shows an image of dentifrice	
At this station you are supposed to:	
Enumerate composition of dentifrice	
List any 5 brand names of fluoridated dentifrices	

MARKING PATTERN

Candidate Reg No:

Examined by:

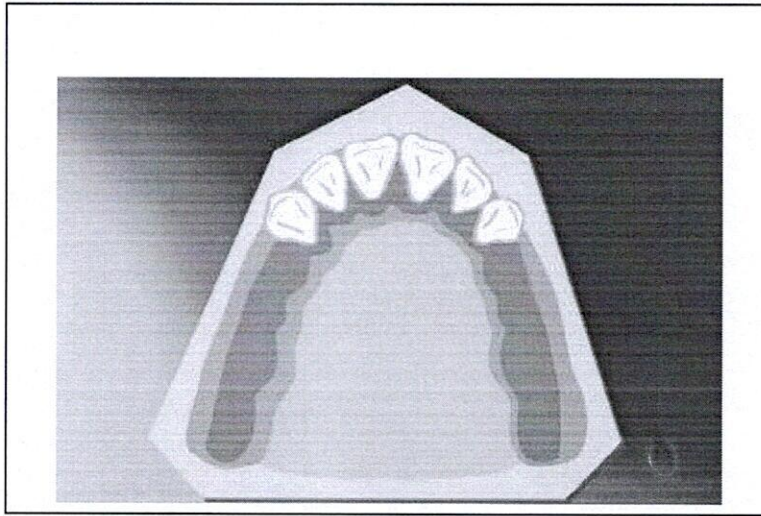
List of Competency	Weightage	Done	Partially done	Not done
1. Knowledge	2.5			
2. Knowledge	2.5			
Marks obtained			Out of 5	

Total marks out of 5


 PRINCIPAL
 SRI VENKATESHWARAA DENTAL COLLEGE
 ARIYUR, PUDUCHERRY - 605 102

Diagnostic Aspects in Partially edentulous situations

S-1 : [Type to expand]

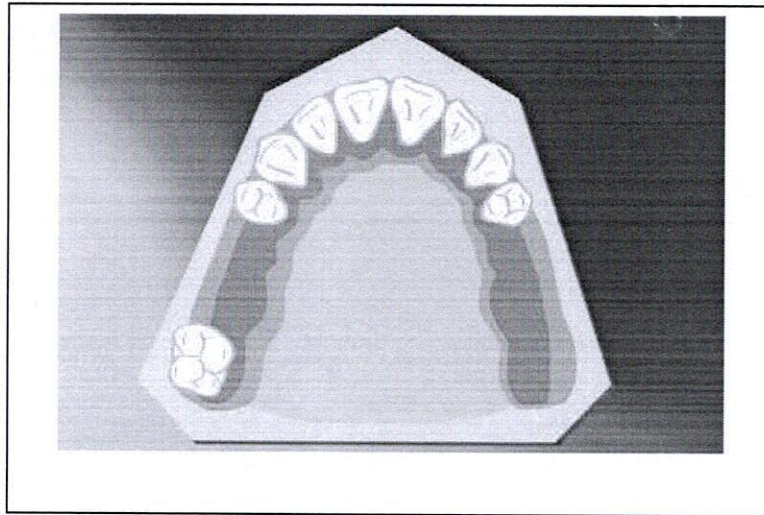


Resources provided	Figure of an Edentulous Cast		
Description	Observed / Response		
Information about the scenario			
At this station you are supposed to			
Answer the Following / Perform the following			
Criteria	Done [1mark]	Partially done [Half of the marks]	Not done [0marks]
1. What is the type of major connector used in this scenario? (1) 2. Which tooth receives direct retainer? (1) 3. What would be the type of direct retainer? (3)			

Total marks out of 5

PRINCIPAL
SRI VENKATESHWARAA DENTAL COLLEGE
ARIYUR, PUDUCHERRY - 605 102

S-1 : [Type to expand]

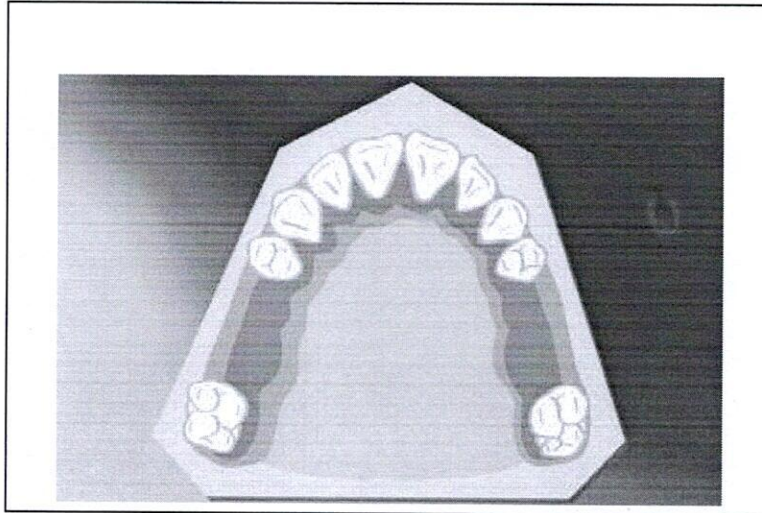


Resources provided	Figure of an edentulous cast		
Description	Observed / Response		
Information about the scenario			
At this station you are supposed to			
Answer the Following / Perform the following			
Criteria	Done [1mark]	Partially done [Partially done [Half of the marks]]	Not done [0marks]
1. What is the type of major connector used in this scenario (1) 2. Which tooth receives the direct retainer? (2) 3. How many director retainer to be placed? (2)			

Total marks out of 5

SRI VENKATESHWARAA DENTAL COLLEGE
 ARIYUR, PUDUCHERRY - 605 102.

S-1 : [Type to expand]

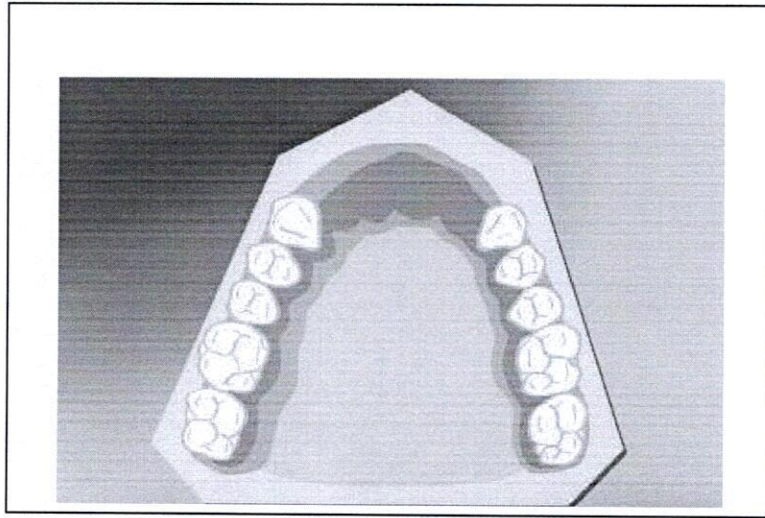


Resources provided	Figure of an edentulous cast		
Description	Observed / Response		
Information about the scenario			
At this station you are supposed to			
Answer the Following / Perform the following			
Criteria	Done [1mark]	Partially done [Partially done [Half of the marks]]	Not done [0marks]
1. What is the type of major connector used in this scenario? (1) 2. Which tooth receives the direct retainer? (1) 3. What would be the type of direct retainer?(3)			

Total marks out of 5



 PRINCIPAL
 SRI VENKATESHWARAA DENTAL COLLEGE
 ARIYUR, PUDUCHERRY - 605 102.

S-1 : [Type to expand]



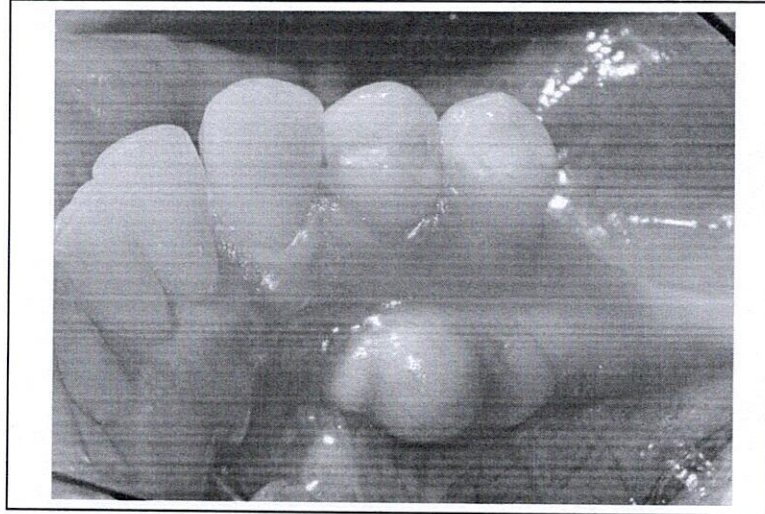
Resources provided	Figure of an edentulous cast		
Description	Observed / Response		
Information about the scenario			
At this station you are supposed to			
Answer the Following / Perform the following			
Criteria	Done [1mark]	Partially done [Partially done [Half of the marks]	Not done [0marks]
<ol style="list-style-type: none"> 1. What is the type of major connector used in this scenario (1) 2. Mention the factor which decides the type of major connector (2) 3. Which tooth receives the direct retainer? (1) 4. What would be the type of direct retainer? (1) 			

Total marks out of 5


 PRINCIPAL
 SRI VENKATESHWARAA DENTAL COLLEGE
 ARYUR, PUDUCHERRY - 605 102.

Treatment planning aspects in Partially edentulous situations

S-1 : [Type to expand]



Resources provided	Picture of a clinical condition		
Description	Observed / Response		
Information about the scenario			
At this station you are supposed to			
Answer the Following / Perform the following			
Criteria	Done [1mark]	Partially done [Partially done [Half of the marks]]	Not done [0marks]
1. What is this clinical condition (1) 2. What would be the type of major connector if this condition is surgically managed to replace 46 and 47? (1) 4. Which tooth receives the direct retainer?(2)			

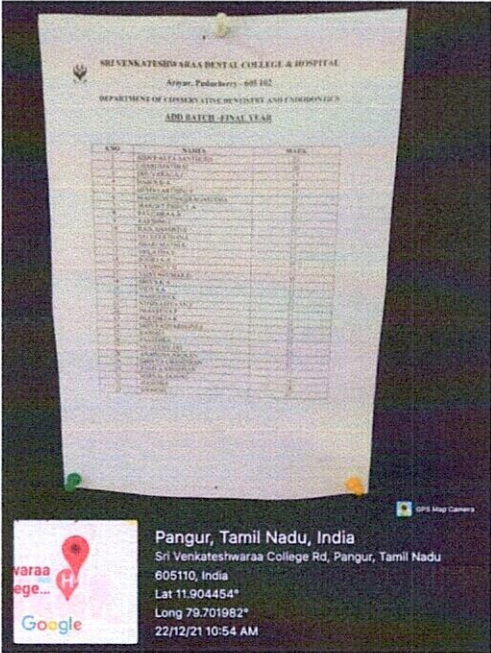
Total marks out of 5

PRINCIPAL
 SRI VENKATESWARA DENTAL COLLEGE
 ARYUR, PUDUCHERRY - 605 102

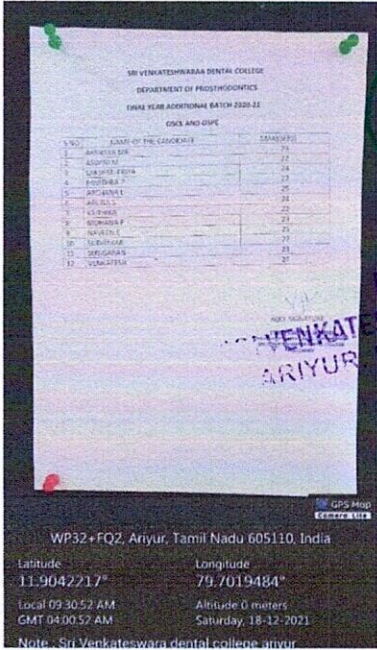



OSCE SYSTEM OF CONDUCTING EXAMINATION

DEPARTMENT OF CONSERVATIVE ENDODONTICS





DEPARTMENT OF PROSTHODONTICS



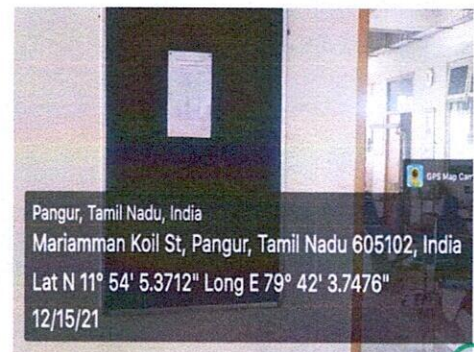
PRINCIPAL
 SRI VENKATESHWARA DENTAL COLLEGE
 PUDUCHERRY - 605 102



DEPARTMENT OF PERIODONTICS



DEPARTMENT OF PEDODONTICS



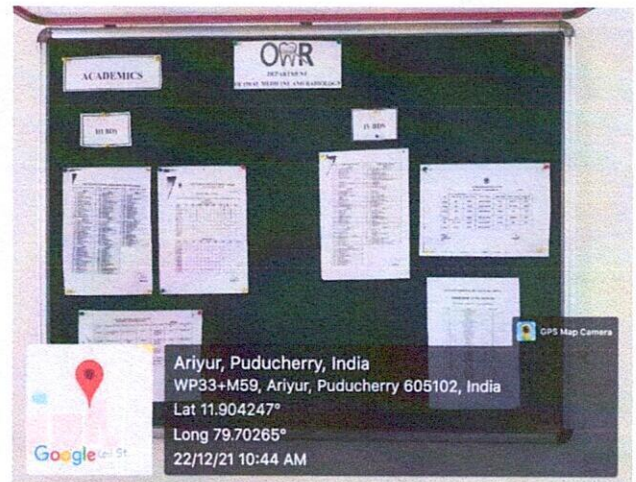

3	CHANDRASEKAR	17
2	DEVIARAJAN	17
4	HAROLD	18
	HANNAKANDU	19
5	HEMANTHAKRISHNAN	17
6	INDUJITHA	21
7	IRISHAN KUNDA	22
8	JAYATHARAS	24
9	JAYARAJ	24
10	JAYARAJ	24
11	JAYARAJ	24
12	JAYARAJ	24
13	JAYARAJ	24
14	JAYARAJ	24
15	JAYARAJ	24
16	JAYARAJ	24
17	JAYARAJ	24

Principal & Head of the Department
Faculty of Public Health Dentistry &
Oral and Maxillofacial Surgery
Ariyur, Puducherry-605102

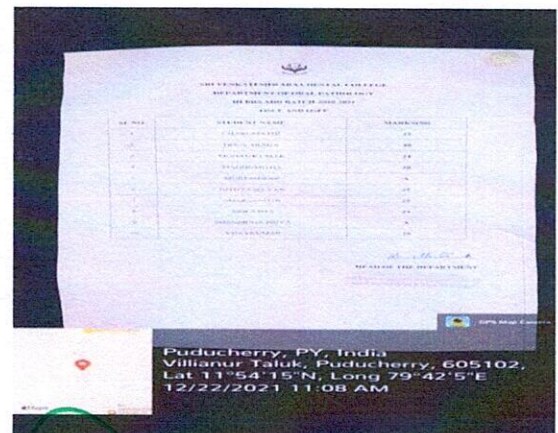

PRINCIPAL
SRI VENKATESHWARA DENTAL COLLEGE
ARIYUR, PUDUCHERRY - 605102



DEPARTMENT OF ORAL MEDICINE & RADIOLOGY



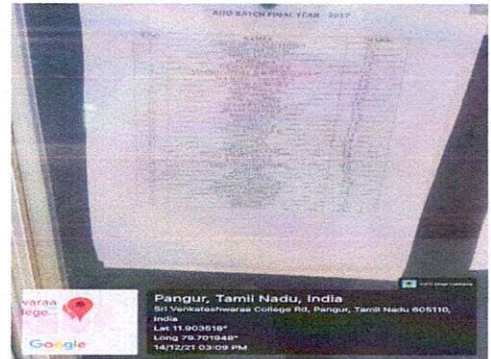
DEPARTMENT OF ORAL PATHOLOGY



PRINCIPAL
SRI VENKATESHWARAA DENTAL COLLEGE
ARIYUR, PUDUCHERRY - 605 102.



DEPARTMENT OF ORAL AND MAXILLOFACIAL SURGERY



DEPARTMENT OF ORTHODONTICS



PRINCIPAL
SRI VENKATESHWARAA DENTAL C
ARIYUR, PUDUCHERRY - 605 :