

GERIATRIC AND PEDIATRIC FRACTURES OF MAXILLOFACIAL REGION

Dept of omfs
SVDC

- ▣ *Closed Reduction*

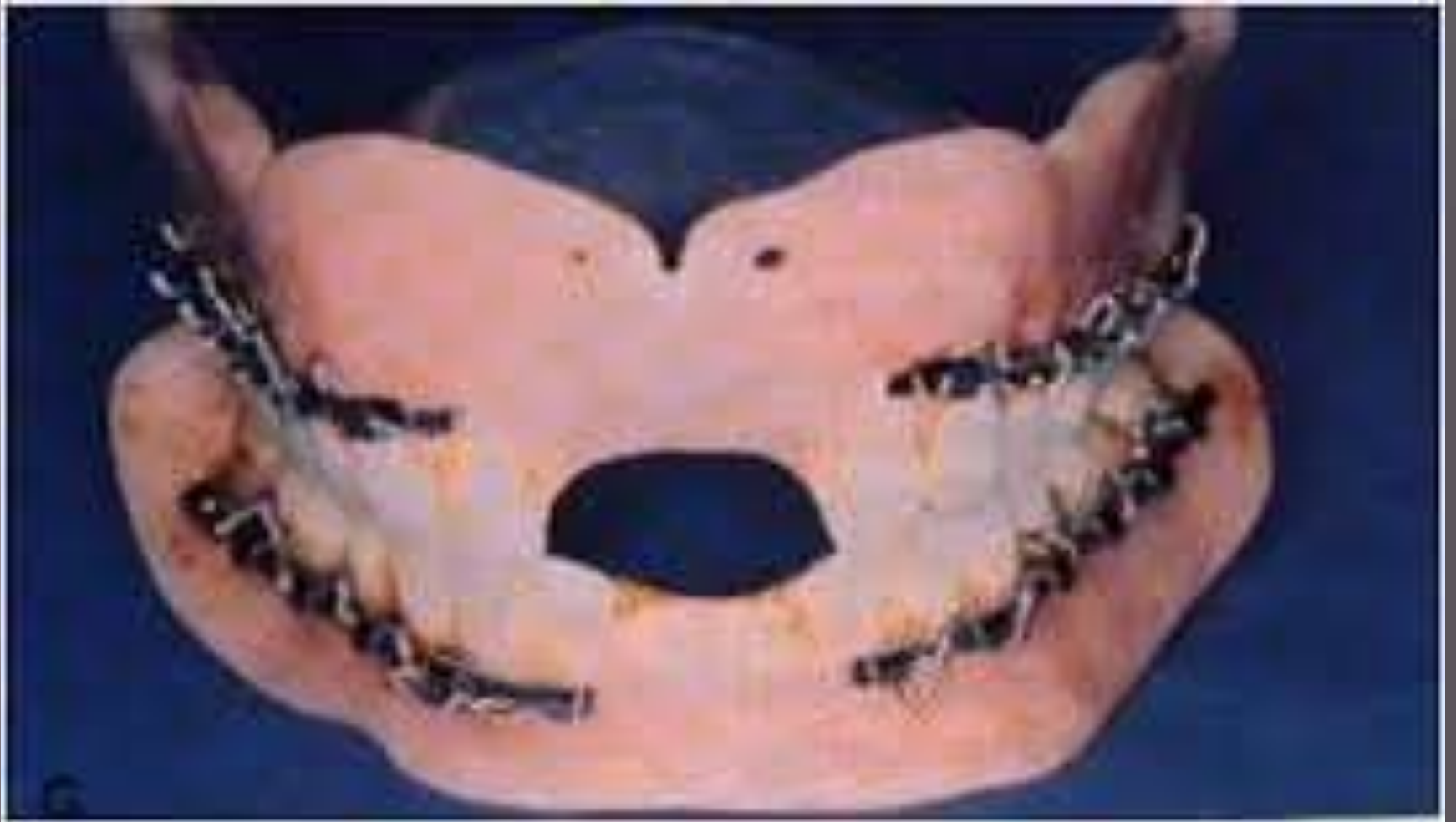- ▣ *∪ Denture or acrylic splint wired to the superior surface of the atrophic mandibular ridge*

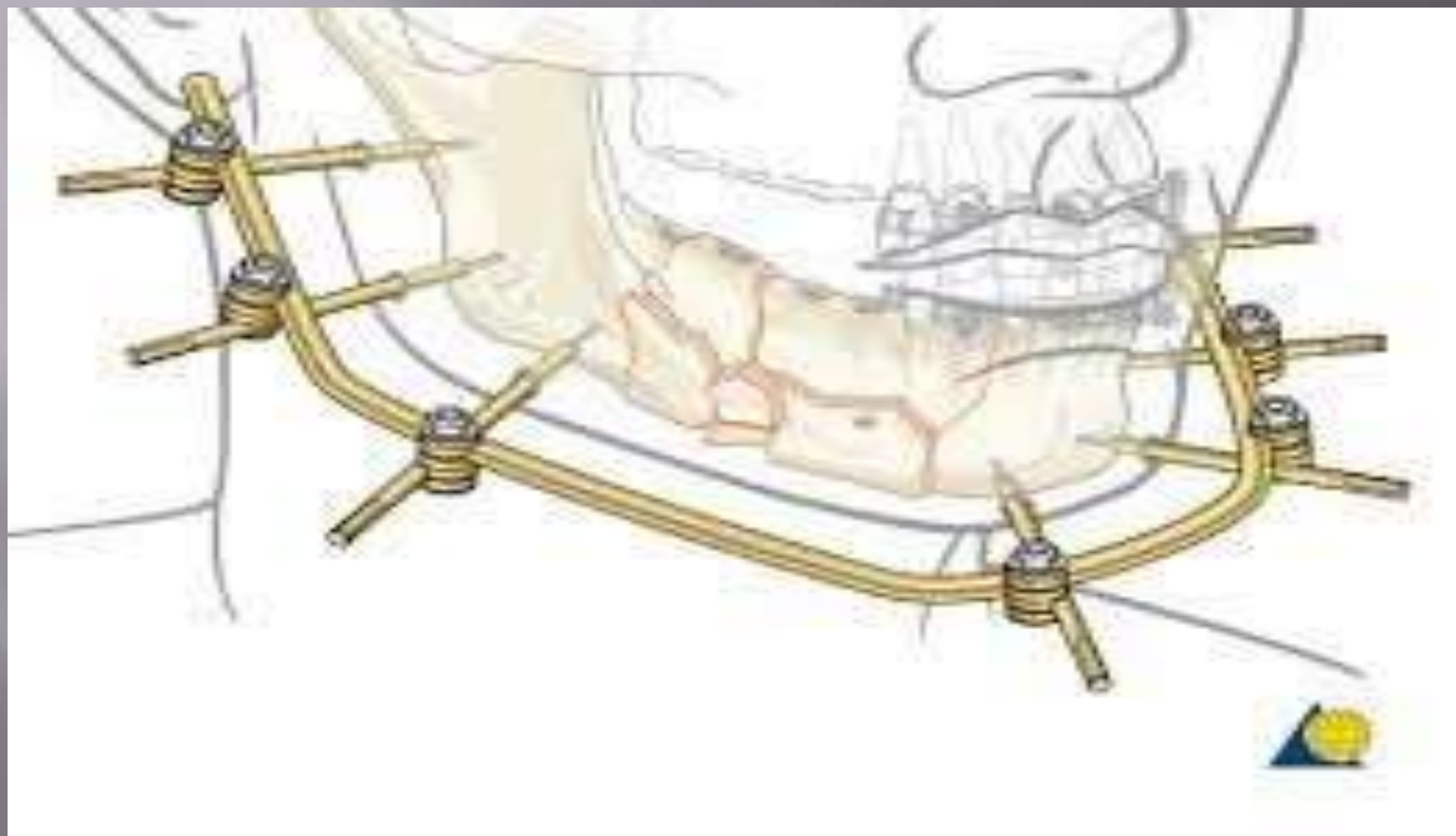
- ▣ *∪ Gunning splint*

- ▣ *∪ Biphasic external pin appliance*

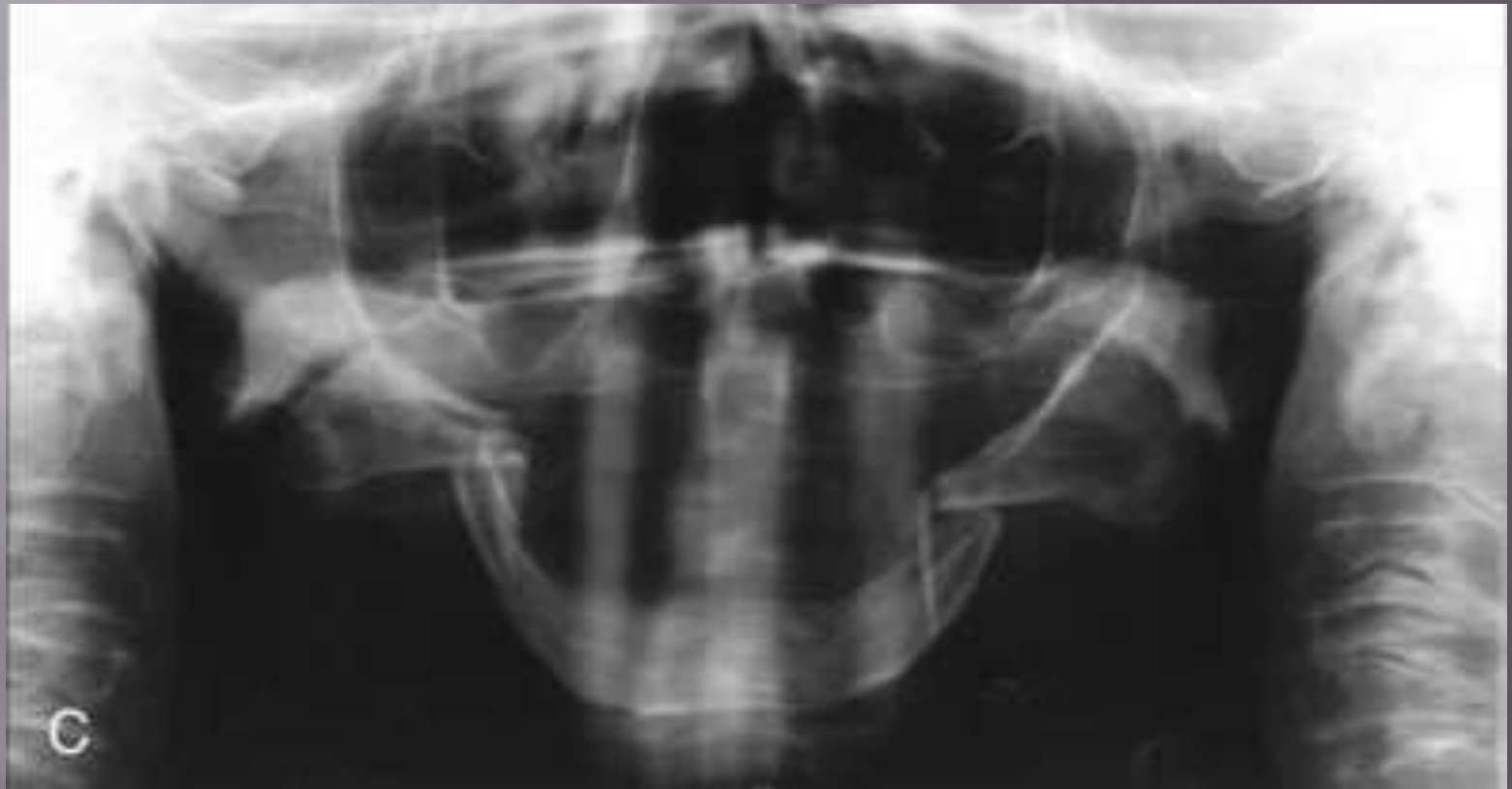
- ▣ *∪ Intramedullary pinning*

THOMAS BRYAN GUNNING- 1885

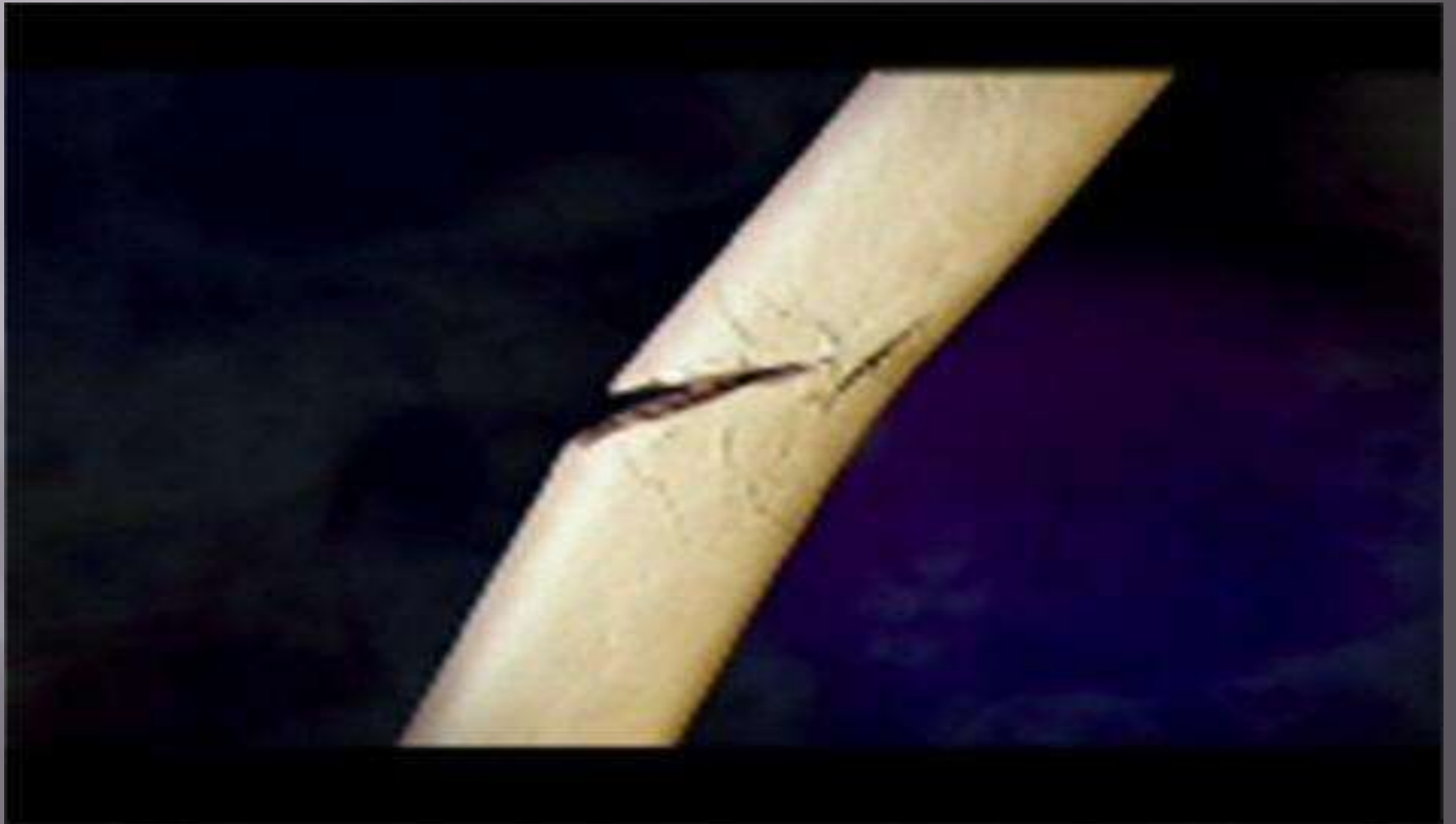


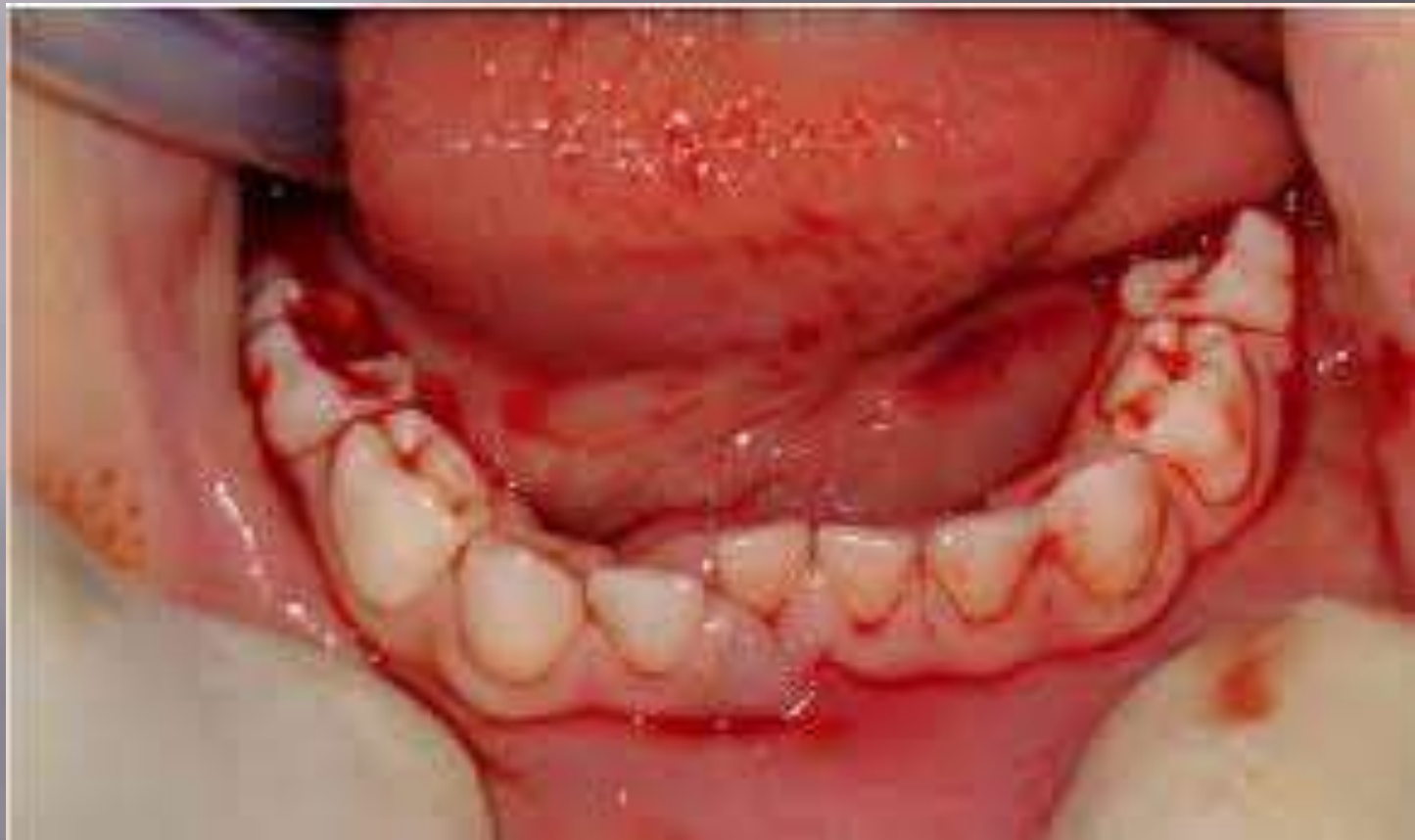
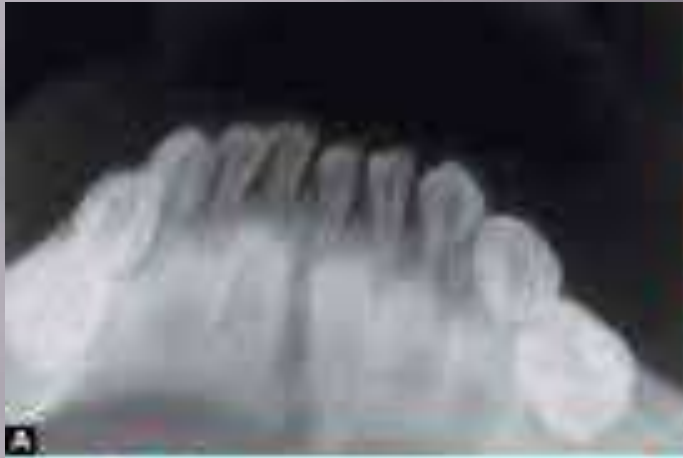Bucket handle fracture



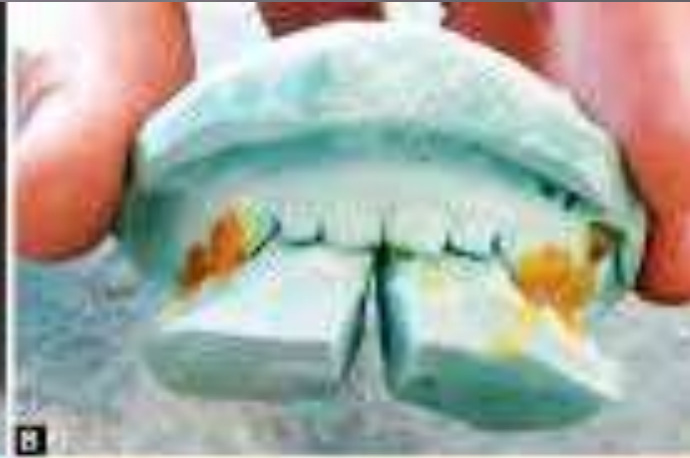Greenstick fractures



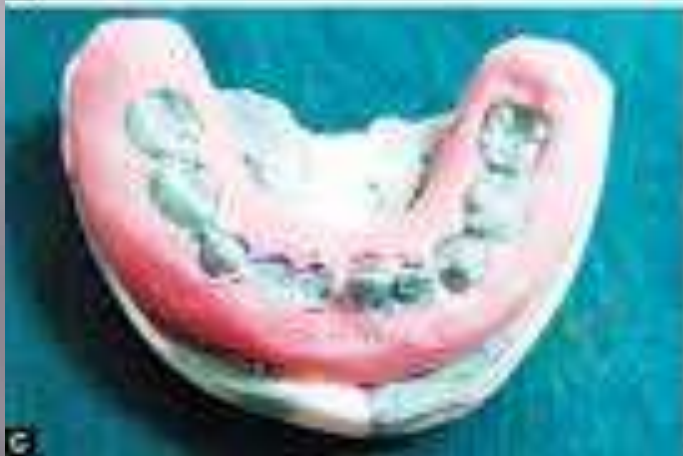



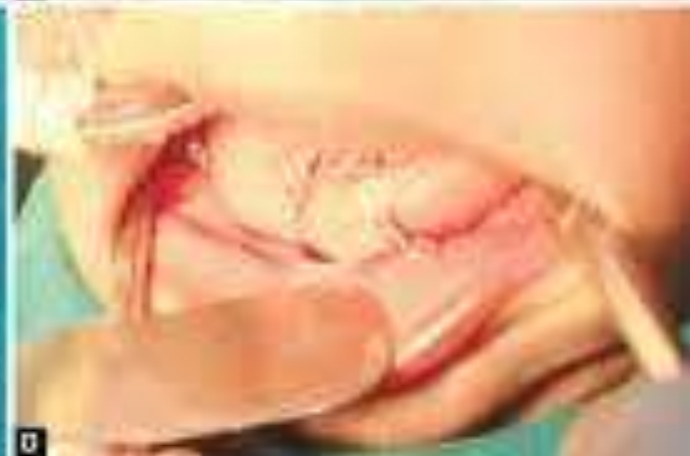A



B

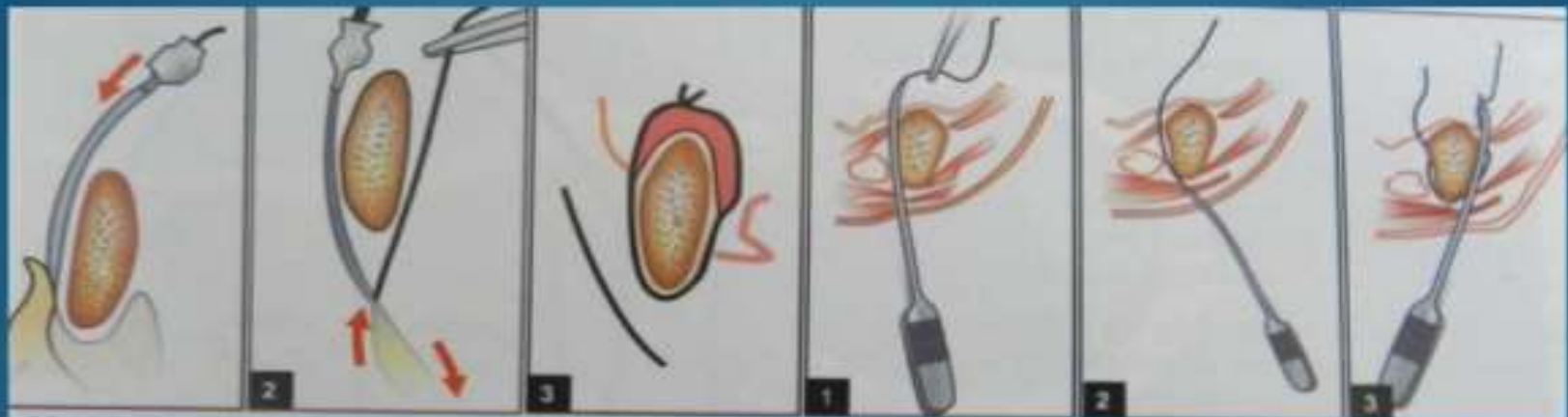


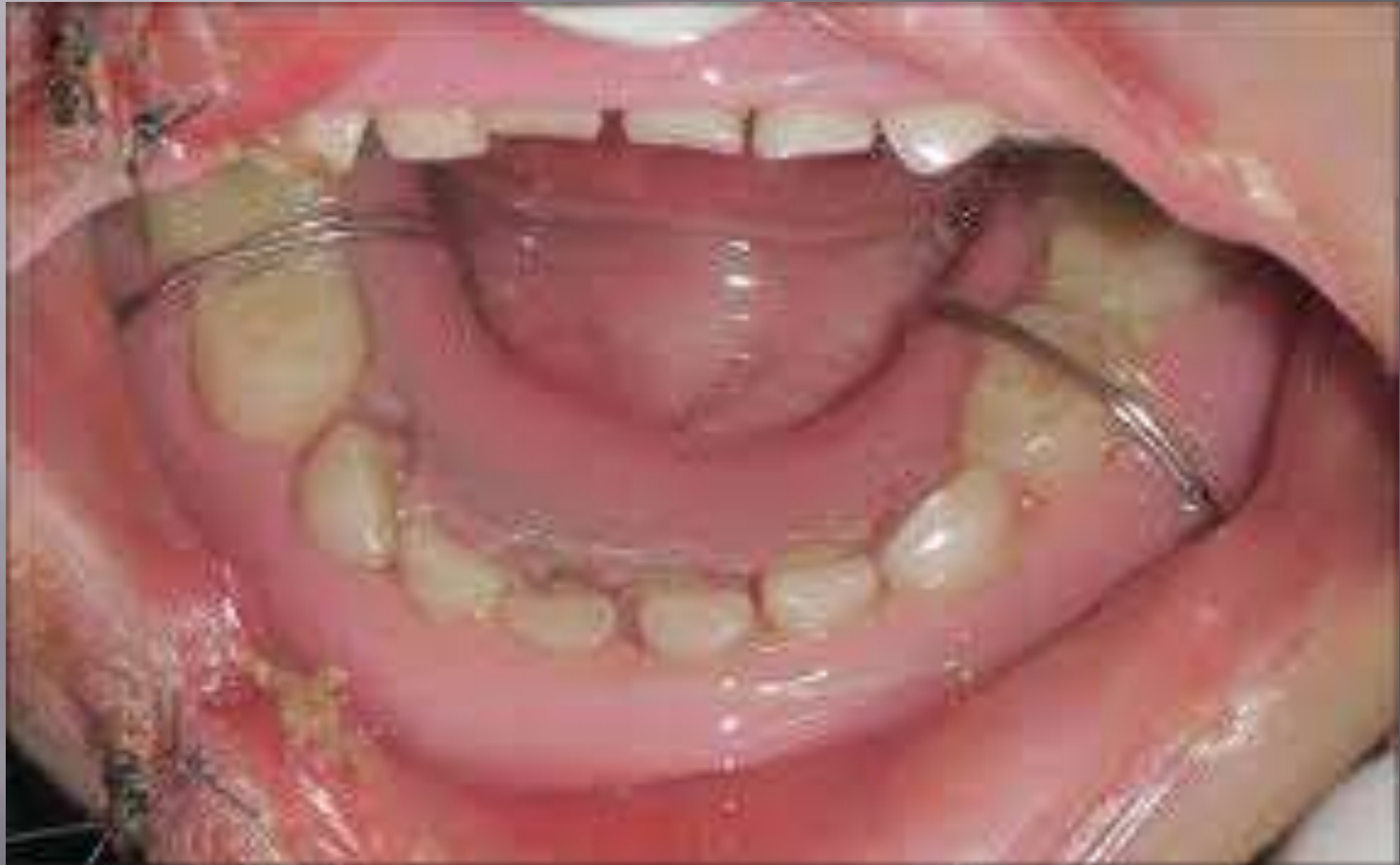C

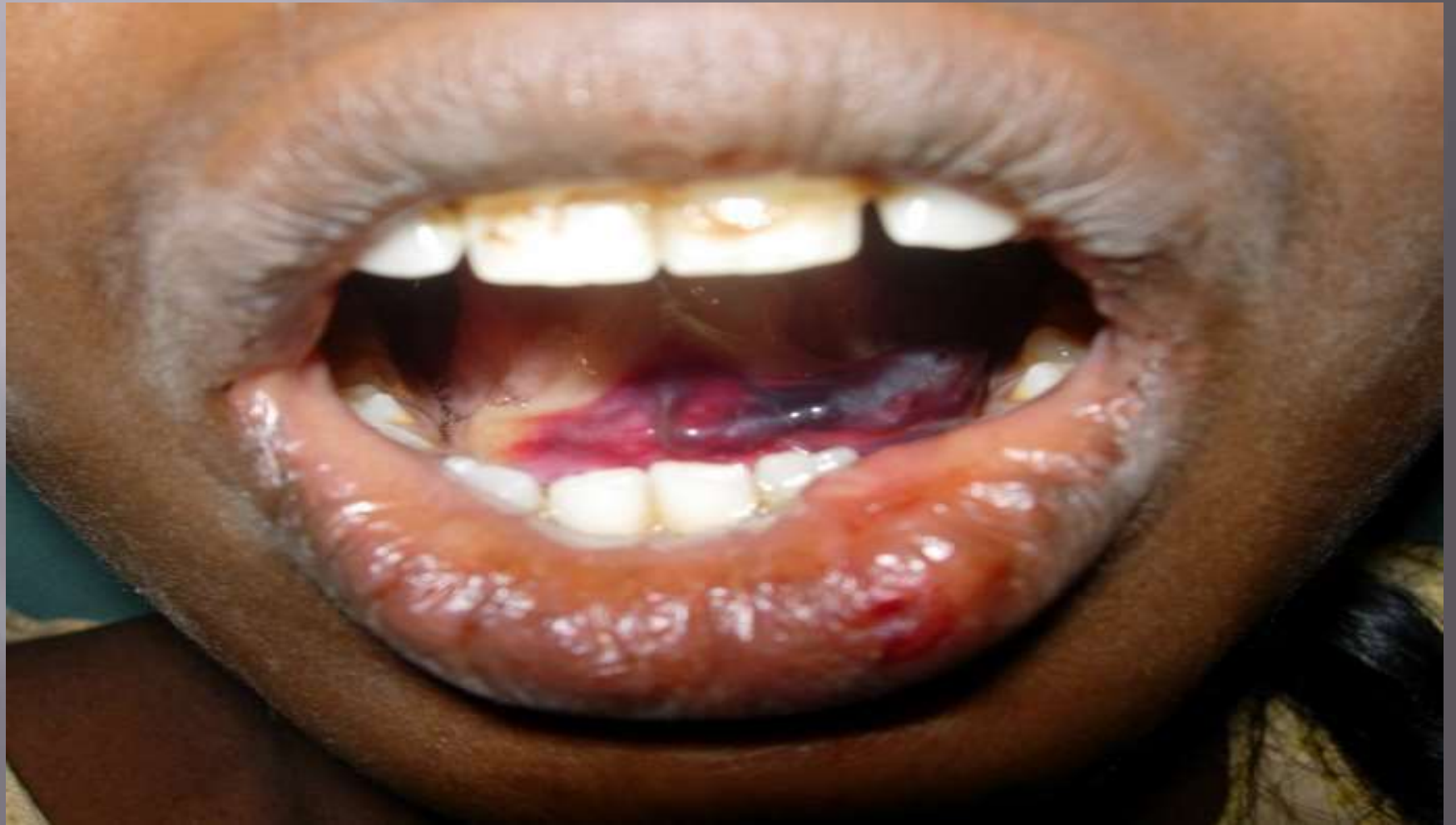

D

Circummandibular wiring





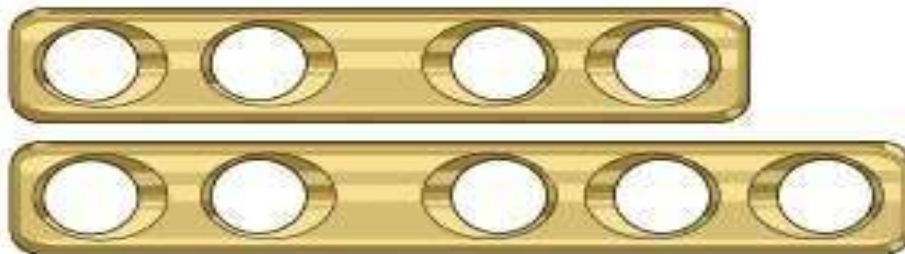




Mandible plate 2.0



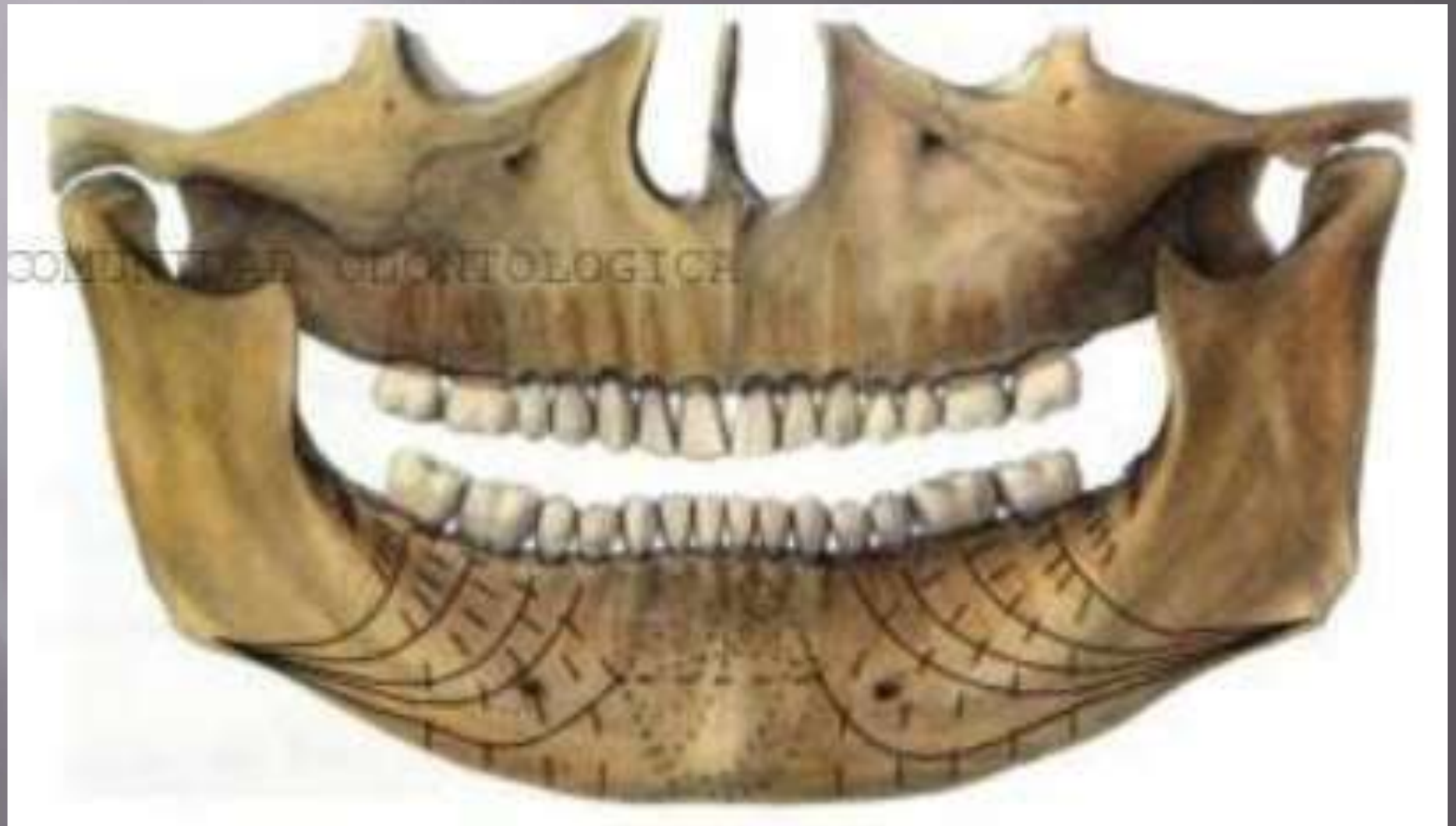
Small/Medium profile locking plate 2.0

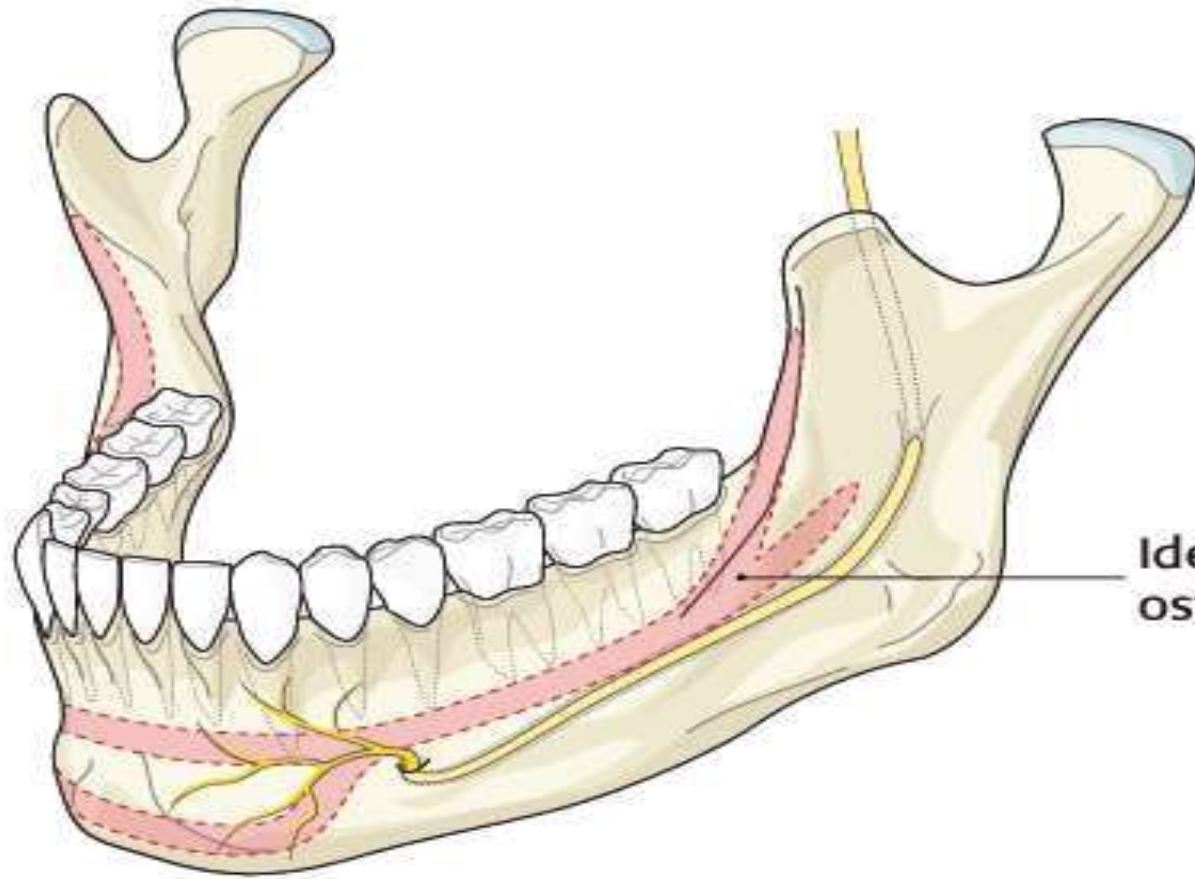


Dynamic compression plate 2.0



Champy's Osteosynthesis lines

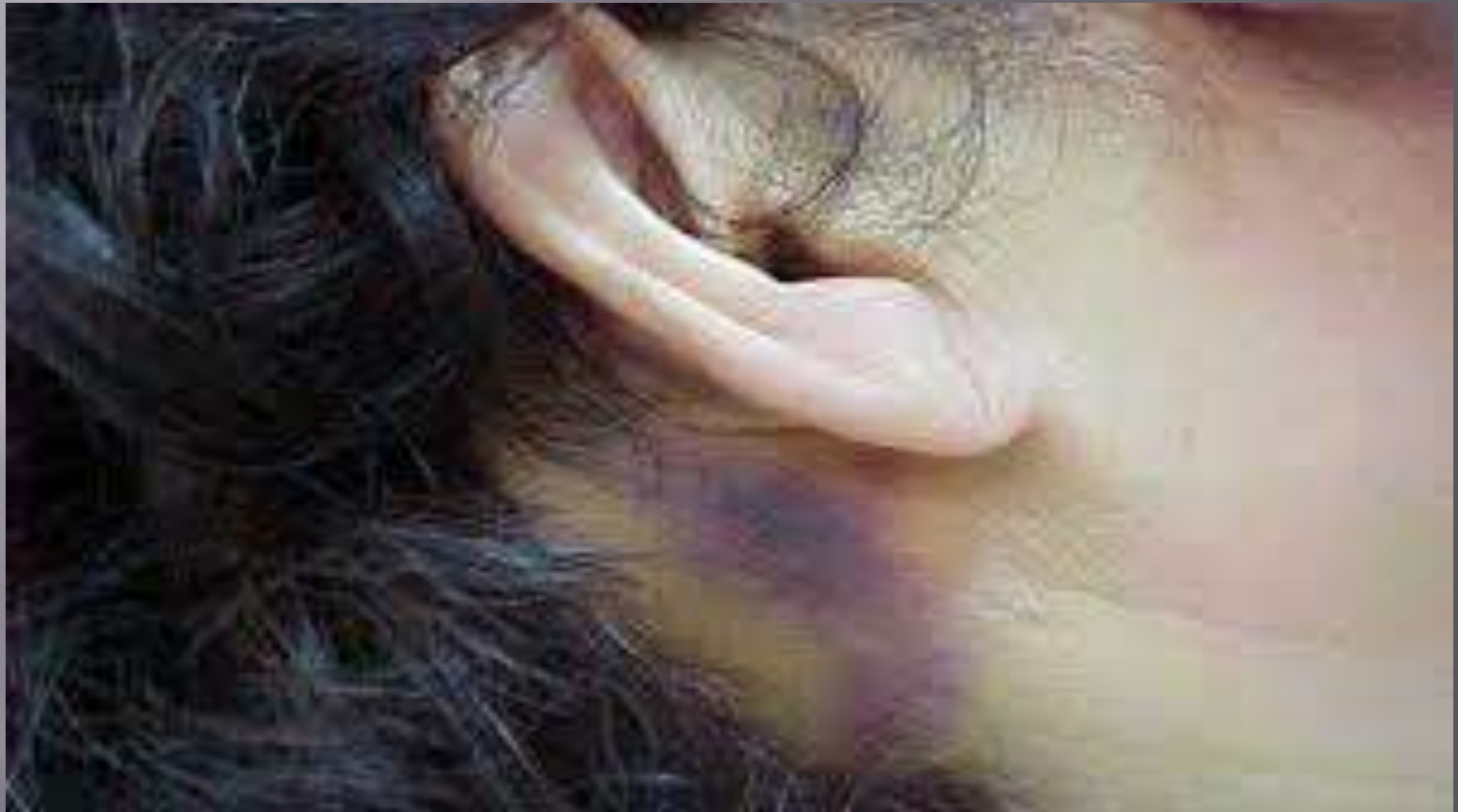



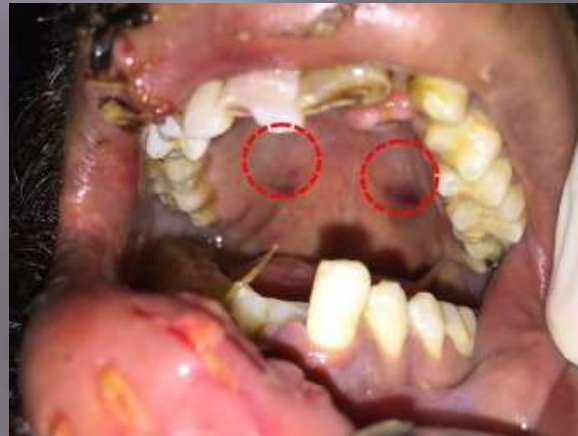Ideal line of osteosynthesis



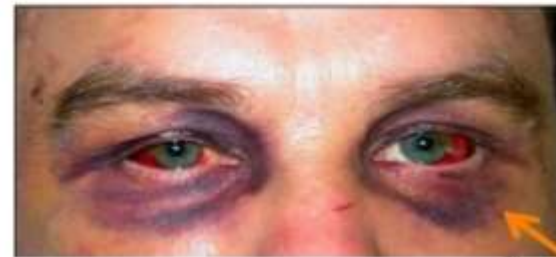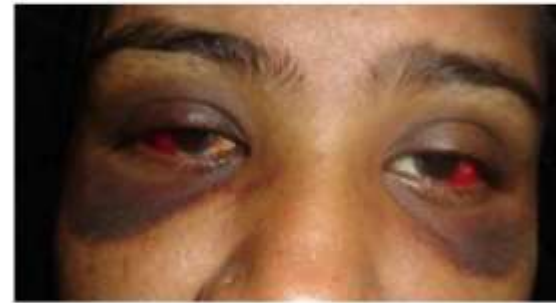Battles sign



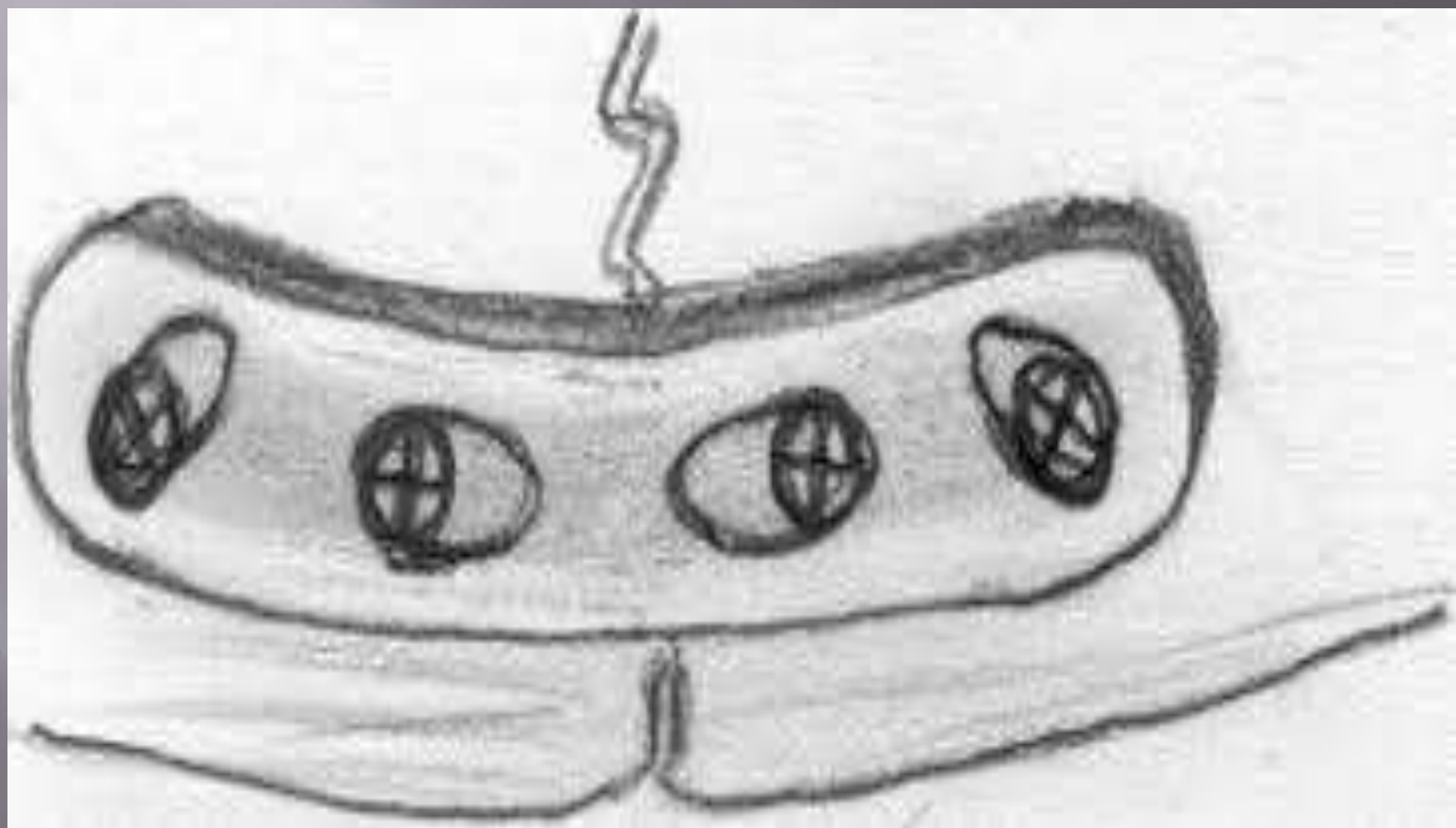
guerin's sign



- Bilateral circumorbital ecchymoses – panda facies, or racoon eyes
- Bilateral subconjunctival ecchymosis







Suspension wiring

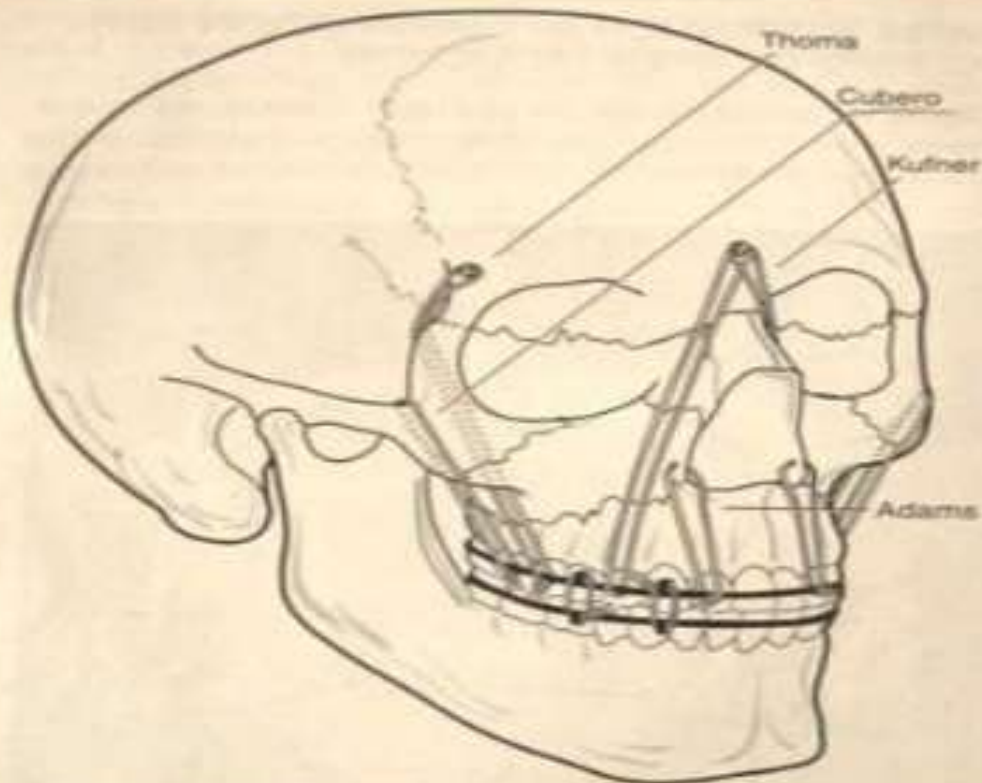


Fig. 6-6 Different types of internal fixation by wire suspension according to Thoma,²⁸ Kufner,²⁹ Adams,^{30,31} and Cubero.³²

Parade ground fractures

jjj

Mechanism of injury

2. Kinetic energy derived from the moving individual striking a static object

ex a child slipping and striking the pavement or a fall during an epileptic fit or parade ground fracture

